

Spontaneous descent of a cryptorchid testicle after the first stage of a planned 2 stage laparoscopic Fowler-Stephens orchidopexy

Adam Stewart, MD, David Hill MD

Division of Urology, University of Tennessee Graduate School of Medicine, Knoxville, Tennessee, USA

STEWART A, HILL D. Spontaneous descent of a cryptorchid testicle after the first stage of a planned 2 stage laparoscopic Fowler-Stephens orchidopexy. The Canadian Journal of Urology. 2010;17(5):5403-5404.

We present the case of a 6-month-old boy with an intra-abdominal testicle that spontaneously descended into the

scrotum after the first stage of a planned 2 stage laparoscopic Fowler-Stephens orchidopexy. To our knowledge this has not been reported.

Key Words: orchidopexy, undescended testes, Fowler Stephens

Case report

A 6-month-old healthy white male presented to our clinic with a non-palpable, undescended testicle on the right. He was born at 38 weeks gestation with a birth weight of 6 pounds 12 ounces. On physical exam the patient had a normal circumcised phallus and a normal left testicle in the scrotum. There was no palpable right testicle in the scrotum or inguinal canal. After discussion with the patient's parents, the patient was taken to the operating room for laparoscopy to determine the location of the right testis.

At the time of laparoscopy the left side was inspected and found to be normal without obvious hernia at the internal ring. However, upon inspection

of the right side, an intra-abdominal testicle was visualized near the internal ring. The decision was made to perform the first stage of a 2 stage Fowler-Stephens orchidopexy. We cauterized and divided the spermatic vessels, but did not manipulate the right testicle, Figure 1. We then closed the incisions with the intention of performing the second stage of the Fowler-Stephens orchidopexy 6 months later.

Postoperatively the patient did very well. His incisions were healing as expected and his genital exam remained unchanged after two postoperative visits. Three months after surgery the patient's father called the office stating that his son's testicle had descended into the scrotum. Physical exam showed the patient's right testicle had spontaneously descended into a normal anatomic position in the scrotum. There was still a palpable right inguinal hernia so 3 months later we repaired his hernia and his right testicle was still in good position in the right hemi-scrotum.

Accepted for publication April 2010

Address correspondence to Dr. Adam Stewart, Division of Urology, 1924 Alcoa Highway, Knoxville, TN 37920 USA

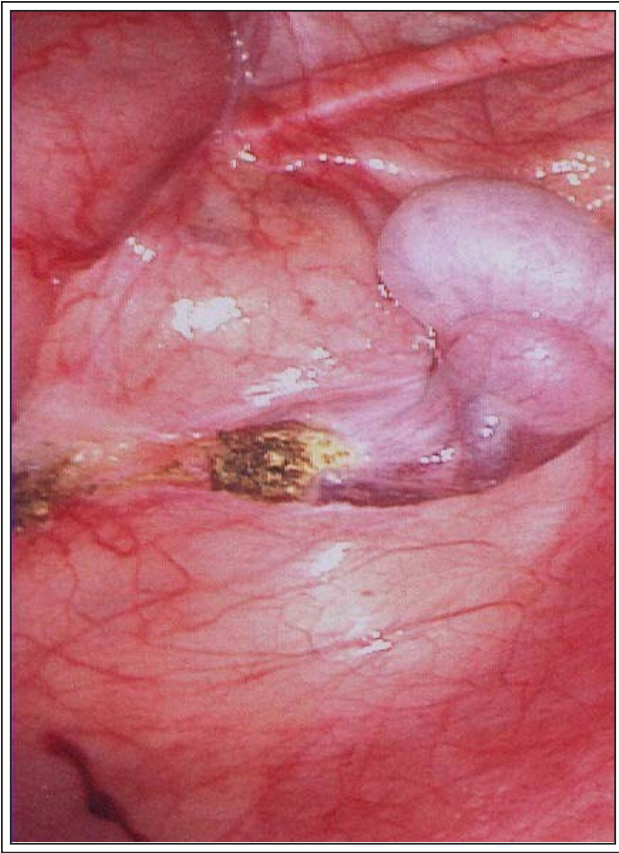


Figure 1. Intra-abdominal testicle after spermatic cord ligation with electrocautery. The internal ring is not visible in this picture.

Discussion

Numerous events must take place in order for the fetal testicle to descend properly into the scrotum during development.¹ Cryptorchidism happens when the testicle fails to descend completely into the dependent portion of the scrotum. During fetal development the testicle typically lies dormant in the abdomen until around the 23rd week of gestation. At this time the processus vaginalis elongates into the scrotum, which will allow the passage of the gubernaculum, epididymis, and testes through the inguinal canal into the scrotum.²⁻³ Berkowitz et al reported the rate of cryptorchidism in 6935 newborn boys declined from 3.7% at birth to 1.0% by 3 months of age. After 6 months of age, spontaneous descent is rare.⁴ Another series published by Wenzler et al, showed that only 6.9% of cryptorchid testes will spontaneously descend after 6 months of age.⁵ We recognize that while it is not common for a testicle to descend spontaneously after 6 months, it is possible our patient's testicle could have

descended spontaneously if we had not taken him to the operating room.

When performing laparoscopy for an intra-abdominal, the internal ring is identified bilaterally. Possible findings include cord structures entering the internal ring, blind ending vessels above the internal ring, or an intra-abdominal testis. In a two staged Fowler-Stephens orchidopexy the testis is not manipulated after the spermatic vessels are ligated or clipped until 6 months later when the testis is brought down into the scrotum using the same technique previously described.⁶⁻⁷ The technique we have used to address the spermatic cord has always been to ligate the cord while others choose to simply clip the spermatic cord and not divide it. For those few testicles that may proceed to descend after 6 months of age, dividing the vessels may actually facilitate or at least not hinder further descent. Clipping the vessels alone could conceivably inhibit further descent of a testicle that might continue to descend spontaneously.

Conclusion

To our knowledge spontaneous descent to a normal anatomical position has not been reported after the first stage of a planned two stage Fowler Stephens orchidopexy. □

References

1. Scorer CG. The anatomy of testicular descent - normal and incomplete. *Br J Surg* 1962;49:357-367.
2. Heyns CF. The gubernaculum during testicular descent in the human fetus. *J Anat* 1987;153:93-112.
3. Backhouse KM. Embryology of the normal and cryptorchid testis. In *The Undescended Testis* ed. E. W. Fonkalsrud & W. Mengel, 1981:5-29.
4. Wenzler DL, Bloom DA, Park JM. What is the rate of spontaneous testicular descent in infants with cryptorchidism? *J Urol* 2004;171(2 Pt 1):849-851.
5. Berkowitz GS, Lapinski RH, Dolgin SE, Gazella JG, Bodian CA, Holzman IR. Prevalence and natural history of cryptorchidism. *Pediatrics* 1993;92(1):44-49.
6. Denes FT, Saito FJ, Silva FA, Giron AM, Machado M, Srougi M. Laparoscopic diagnosis and treatment of nonpalpable testis. *Int Braz J Urol* 2008;34(3):329-334.
7. Tennenbaum SY, Lerner SE, McAleer IM, Packer MG, Scherz HC, Kaplan GW. Preoperative laparoscopic localization of the nonpalpable testis: a critical analysis of a 10-year experience. *J Urol* 1994;151(3):732-734.