

# *Urolith masquerading as severe acute radiation toxicity: case report*

Daniel Toguri, BScH,<sup>1</sup> D. Andrew Loblaw, MD,<sup>2</sup> Robert K. Nam, MD<sup>3</sup>

<sup>1</sup>Clinical Clerk, Schulich School of Medicine and Dentistry, The University of Western Ontario, London, Ontario, Canada

<sup>2</sup>Department of Radiation Oncology, Odette Cancer Centre, Sunnybrook Health Sciences Centre, University of Toronto, Toronto, Ontario, Canada

<sup>3</sup>Division of Urology, Sunnybrook Health Sciences Centre, University of Toronto, Toronto, Ontario, Canada

---

TOGURI D, LOBLAW A, NAM RK. Urolith masquerading as severe acute radiation toxicity: case report. *The Canadian Journal of Urology*. 2010;17(1):5040-5043.

**Introduction:** Postoperative radiotherapy after radical prostatectomy has been shown to improve numerous outcomes for selected patients in mature randomized controlled trials. During treatment patients usually experience mild to moderate urinary symptoms, lower gastrointestinal symptoms and tiredness. We describe an unusual case of a patient experiencing severe, culture negative urinary symptoms early in a course of salvage radiotherapy.

**Materials and methods:** A patient's history was retrospectively derived from a single institution.

**Results:** A total radiation dosage of 66 Gy in 33 fractions was to be delivered to the prostate bed by intensity modulated radiation therapy. Urinary symptoms consisting of hematuria, dysuria and urination of cellular debris developed very early during the treatment, were not related to infection and were refractory to breaks from radiation therapy. Computed tomography imaging revealed a 3.5 cm diameter urolith in the posterior bladder. Urinary symptoms resolved after surgical management consisting of, cystolitholapaxy with laser cystoscopy.

**Conclusions:** While rare, urolithiasis should be considered when severe, early, culture negative dysuria develops on radiotherapy for prostate cancer.

**Key Words:** bladder calculi, radiation toxicity, urolith

---

## Introduction

Postoperative radiotherapy (RT) after radical prostatectomy can be given as adjuvant or salvage treatment. Adjuvant treatment is usually given within 4 months of surgery and is indicated for the presence of risk factors for recurrence; the PSA is usually undetectable.<sup>1-3</sup> Salvage postoperative RT is indicated for a rising PSA after radical prostatectomy.

Postoperative adjuvant RT has been shown to improve numerous outcomes for patients with

pathologic T3 status or positive margins. There are now three RCTs demonstrating improved biochemical DFS (bDFS), decreased local recurrence, reduced need for androgen ablation therapy with adjuvant radiotherapy for patients with pathologic extracapsular/seminal vesicle involvement (pT3) or positive margins.<sup>1-3</sup> Most importantly the SWOG 8794 study has recently published their 12 year follow up results, now showing statistically significant improvements in overall survival (median overall survival 15.2 y versus 13.3 y) and distant metastatic DFS (median DMDFS 14.7 y versus 12.9 y).<sup>2</sup> Salvage RT does provide durable bDFS<sup>4,5</sup> and mounting evidence supports better bDFS with "early salvage" RT.<sup>6</sup>

As a result, one expects the proportion of patients receiving postoperative (adjuvant and salvage) radiation to increase. During postoperative radiation, patients usually experience mild to moderate urinary

---

Accepted for publication October 2009

Address correspondence to Dr. Andrew Loblaw, Department of Radiation Oncology, Odette Cancer Centre, Sunnybrook Health Sciences Centre, University of Toronto, 2075 Bayview Avenue, Toronto, Ontario M4N 3M5 Canada

symptoms (dysuria, frequency, urgency), lower gastrointestinal symptoms (tenesmus, frequency, urgency, perianal discomfort) and tiredness.<sup>2</sup> Intensity modulated radiotherapy is being used more frequently in the treatment of prostate cancer and for constant target volumes has been associated with fewer side effects.<sup>7</sup> While consensus based target volumes are increasing the volume of irradiated tissue,<sup>8</sup> the treatment is generally very well accepted.

We describe an unusual case of a patient experiencing severe, culture negative urinary symptoms early in a course of salvage radiotherapy which required a break in treatment.

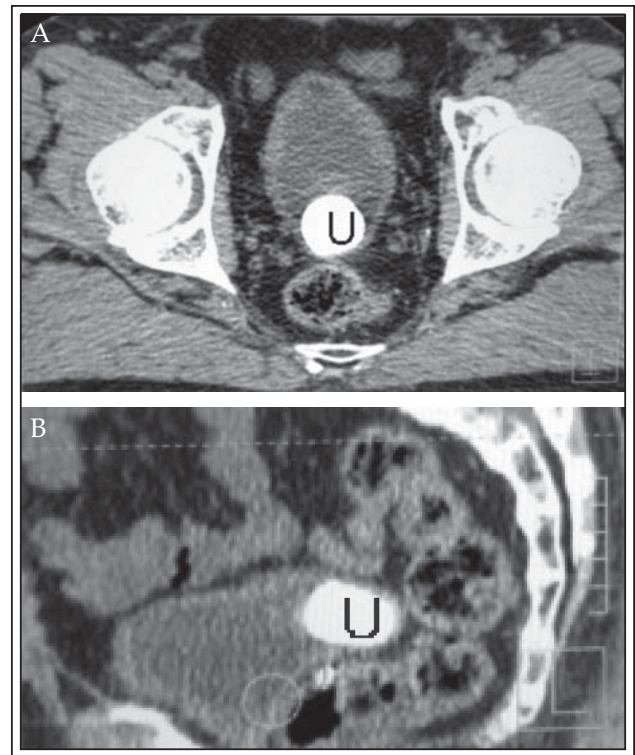
### Case report

A 63-year-old gentleman initially came to medical attention when a routine PSA screen detected a PSA level of 9.5 ng/mL. Pathological analysis of prostate biopsy cores revealed a clinical stage 2 adenocarcinoma, Gleason score 7 (4 + 3) bilaterally, and occupying approximately 25% of the organ volume. A radical prostatectomy was performed 4 months after the elevated PSA was detected.

Three months after the radical prostatectomy, the patient's PSA levels began to rise steadily. The patient was referred to radiation oncology to have salvage radiation therapy for recurrent localized prostate cancer. The radiation treatment plan consisted of a radiation dose of 66 Gy delivered by intensity modulated radiation therapy (IMRT) to the prostate bed in 33 fractions, 5 days per week over 6.5 weeks.

During the first week of radiation treatment the patient developed, hematuria, dysuria and excreted urine containing cellular debris and mucous. After a negative urine culture and sensitivity analysis, these urinary symptoms were attributed to radiation toxicity of the genitourinary tract. As a consequence, a 1 week break in treatment was given. Upon resuming treatment the patient reported that urinary symptoms had progressed. A 2 week treatment break was given without improving symptoms. Radiation therapy was stopped after 15 fractions due to progressive urinary symptoms.

A subsequent planning computed tomography (CT) was performed during the protracted course of treatment, Figure 1. Imaging revealed a large ellipsoid urolith of approximately 3.5 cm in a diverticulum of the posterior bladder. The urolith was managed by cystolitholapaxy with laser cystoscopy. The calculi was vaporized and fragmented and the bladder was irrigated thoroughly. The patient recovered well and found relief from symptoms.



**Figure 1.** A planning CT image of a bladder urolith, 'U', in a diverticulum of the posterior bladder as seen in an axial view (A) and sagittal view (B).

The patient resumed his radiotherapy 2 weeks after cystolitholapaxy and had no severe urinary symptoms for the duration of his radiation and has no late effects from radiotherapy to date.

### Discussion

Postoperative radiation can successfully salvage PSA recurrence after radical prostatectomy,<sup>4</sup> although mature randomized studies now show that early or adjuvant treatment appears to have improved biochemical disease free survival, pelvic control, distant metastatic free survival and overall survival compared to delayed or no postoperative radiotherapy.<sup>1-3</sup>

Postoperative radiotherapy is typically given using three dimensional conformal radiotherapy (3D-CRT); more recently intensity modulated radiotherapy (IMRT) or image guided IMRT (IGRT) systems are been used. IMRT and IGRT are more advanced forms of radiation therapy where more beams, multiple apertures (or segments) per beam and an inverse planning system are used. The end result is a radiation distribution that is more precise (IMRT) and more accurate (IGRT) allowing tighter coverage of target volumes and better avoidance of surrounding normal tissues, particularly the rectum.

While there is a paucity of data comparing 3D-CRT and IMRT for postoperative treatment, there is good sequential cohort demonstrating lower acute and late toxicities with IMRT/IGRT for the primary treatment of localized prostate cancer.<sup>7</sup>

The symptoms that patients experience with radiotherapy for localized prostate cancer can be classified as acute or late. Any toxicity occurring during the radiation treatment or the following 3 months is considered acute<sup>7,9,10</sup> while toxicities occurring 6 months after the conclusion of radiation therapy, or acute toxicities enduring for longer than 3 months, are considered late toxicities.<sup>9,11</sup>

Had the symptoms of the patient in this case been induced by radiation they would be considered acute toxicities. Acute radiation toxicity following postprostatectomy salvage therapy for biochemical recurrence typically includes fatigue, increased bowel frequency and increased urinary obstructive and irritative voiding symptoms.<sup>12</sup> In a review of 12 cases series, on salvage radiation therapy for biochemical failure postprostatectomy, no severe acute radiation toxicities were reported for treatment with radiation doses between 60 Gy and 75.5 Gy, where the majority of cases used radiation dosages in the 60 Gy-66 Gy range.<sup>12</sup>

Similarly, a recent 2008 study of 135 patients, treated with IMRT salvage therapy for biochemical failure postprostatectomy, using a radiation doses of 75 Gy in 37 fractions, reported low incidences of grade 3 genitourinary toxicity; one case of grade 3 dysuria, hematuria, increase frequency and incontinence, each. Grade 2 genitourinary toxicities were found in 28% of patients, most commonly, nocturia, 14%. Grade 2 dysuria was found in only 4% of cases and hematuria only in two patients.<sup>9</sup> It is important to note the timing of these acute side effects. Typically, patients remain asymptomatic for the first 1-2 weeks of radiotherapy then they gradually onset, peaking in intensity about 4-5 weeks into treatment, remain for the duration of treatment and resolve within the first month post-treatment.

The urinary symptoms seen in this case would be abnormally severe for acute genitourinary radiation toxicity: hematuria, dysuria and urination of cellular debris and mucous. In addition, having a patient experience these severe symptoms within the first week of treatment is doubly abnormal. Typically, a physician considers a urinary tract infection as the cause of early irritative voiding symptoms during radiation but in this case urine culture and sensitivity analyses were unyielding.

The bladder urolith constitutes 5% of urinary calculi.<sup>13</sup> A retrospective review of 328 patients found that the most frequent presentation of a bladder urolith was

acute urinary retention (67%) followed by dysuria (40%) and hematuria (23%).<sup>14</sup> In the same study, it was found that the older the patient was the less likely they were to present with acute urinary retention. The size of the bladder urolith influenced the likelihood that the patient would present in acute urinary retention as well; patients with acute urinary retention were more likely (72%) to have bladder calculi of a diameter less than 1 cm.<sup>14</sup>

While uncommon, bladder uroliths or urolithiasis in general can cause the same constellation of symptoms that a patient on prostate radiotherapy might experience. To our knowledge, this is the first published report of a bladder urolith masquerading as a severe acute radiotherapy reaction. Urolithiasis should be considered in the differential for patients on prostate radiotherapy with early, severe, culture negative irritative voiding symptoms and/or hematuria.

## Conclusions

While uncommon, bladder uroliths or urolithiasis in general can cause the same constellation of symptoms that a patient on prostate radiotherapy might experience. This should be considered in the differential for patients on prostate radiotherapy with early, severe, culture negative irritative voiding symptoms and/or hematuria. □

---

## References

1. Bolla M, van Poppel H, Collette L, van Cangh P, Vekemans K, Da Pozzo L, de Reijke TM, Verbaeys A, Bosset JF, van Velthoven R, Maréchal JM, Scalliet P, Haustermans K, Piérart M; European Organization for Research and Treatment of Cancer. Postoperative radiotherapy after radical prostatectomy: a randomised controlled trial (EORTC trial 22911). *Lancet* 2005;366(9485):572-578.
2. Thompson IM, Tangen CM, Paradelo J, Lucia MS, Miller G, Troyer D, Messing E, Forman J, Chin J, Swanson G, Canby-Hagino E, Crawford ED. Adjuvant radiotherapy for pathological T3N0M0 prostate cancer significantly reduces risk of metastases and improves survival: long term follow up of a randomized clinical trial. *J Urol* 2009;181(3):956-962.
3. Wiegel T, Bottke D, Willich N et al. Phase III results of adjuvant radiotherapy (RT) versus "wait and see" (WS) in patients with pT3 prostate cancer following radical prostatectomy (RP) (ARO 96-02/AUO AP09/95). *J Clin Oncol* 2005 ASCO Annual Meeting Proceedings 2005;23(16S):abstract 4513.
4. Choo R, Hruby G, Hong J, Hong E, DeBoer G, Danjoux C, Morton G, Klotz L, Bhak E, Flavin A. Positive resection margin and/or pathologic T3 adenocarcinoma of prostate with undetectable postoperative prostate-specific antigen after radical prostatectomy: to irradiate or not? *Int J Radiat Oncol Biol Phys* 2002;52(3):674-680.

5. Stephenson AJ, Scardino PT, Kattan MW, Pisansky TM, Slawin KM, Klein EA, Anscher MS, Michalski JM, Sandler HM, Lin DW, Forman JD, Zelefsky MJ, Kestin LL, Roehrborn CG, Catton CN, DeWeese TL, Liauw SL, Valicenti RK, Kuban DA, Pollack A. Predicting the outcome of salvage radiation therapy for recurrent prostate cancer after radical prostatectomy. *J Clin Oncol* 2007;25(15):2035-2041.
6. Trabulsi EJ, Valicenti RK, Hanlon AL, Pisansky TM, Sandler HM, Kuban DA, Catton CN, Michalski JM, Zelefsky MJ, Kupelian PA, Lin DW, Anscher MS, Slawin KM, Roehrborn CG, Forman JD, Liauw SL, Kestin LL, DeWeese TL, Scardino PT, Stephenson AJ, Pollack A. A multi-institutional matched-control analysis of adjuvant and salvage postoperative radiation therapy for pT3-4N0 prostate cancer. *Urology* 2008;72(6):1298-1302.
7. Zelefsky MJ, Fuks Z, Hunt M, Yamada Y, Marion C, Ling CC, Amols H, Venkatraman ES, Leibel SA. High-dose intensity modulated radiation therapy for prostate cancer: early toxicity and biochemical outcome in 772 patients. *Int J Radiat Oncol Biol Phys* 2002;53(5):1111-1116.
8. Michalski JM, Lawton C, El Naqa I, Ritter M, O'Meara E, Seider MJ, Lee WR, Rosenthal SA, Pisansky T, Catton C, Valicenti RK, Zietman AL, Bosch WR, Sandler H, Buyyounouski MK, Menard C. Development of RTOG consensus guidelines for the definition of the clinical target volume for postoperative conformal radiation therapy for prostate cancer. *Int J Radiat Oncol Biol Phys* 2009; Apr 23. [Epub ahead of print].
9. De Meerleer G, Fonteyne V, Meersschout S, Van den Broecke C, Villeirs G, Lumen N, Ost P, Vandecasteele K, De Neve W. Salvage intensity-modulated radiotherapy for rising PSA after radical prostatectomy. *Radiother Oncol* 2008;89(2):205-213.
10. De Meerleer G, Vakaet L, Meersschout S, Villeirs G, Verbaeys A, Oosterlinck W, De Neve W. Intensity-modulated radiotherapy as primary treatment for prostate cancer: acute toxicity in 114 patients. *Int J Radiat Oncol Biol Phys* 2004;60(3):777-787.
11. Zelefsky MJ, Aschkenasy E, Kelsen S, Leibel SA. Tolerance and early outcome results of postprostatectomy three-dimensional conformal radiotherapy. *Int J Radiat Oncol Biol Phys* 1997;39(2):327-333.
12. Parker C, Warde P, Catton C. Salvage radiotherapy for PSA failure after radical prostatectomy. *Radiother Oncol* 2001;61(2):107-116.
13. Schwartz BF, Stoller ML. The vesical calculus. *Urol Clin North Am* 2000;27(2):333-346.
14. Hammad FT, Kaya M, Kazim E. Bladder calculi: did the clinical picture change? *Urology* 2006;67(6):1154-1158.