
Fracture of the penis: a radiological or clinical diagnosis? A case series and literature review

Mayank Mohan Agarwal, MCh,¹ Shrawan K. Singh, MCh,¹
Darshan Kumar Sharma, MCh,¹ Priyadarshi Ranjan, MCh,¹ Santosh Kumar, MCh,¹
Vaddi Chandramohan, MCh,² Nitin Gupta, MCh,¹ Naveen C. Acharya, MCh,¹
Vidur Bhalla, MCh,³ Ravimohan Mavuduru, MCh,¹ Arup K. Mandal, MCh¹

¹Postgraduate Institute of Medical Education and Research, Chandigarh, India

²Preeti Urology Clinic, Hyderabad, Andhra Pradesh, India

³Government Multispeciality Hospital, Chandigarh, India

AGARWAL MM, SINGH SK, SHARMA DK, RANJAN P, KUMAR K, CHANDRAMOHAN V, GUPTA N, ACHARYA NC, BHALLA V, MAVUDURU R, MANDAL AK. Fracture of the penis: a radiological or clinical diagnosis? A case series and literature review. The Canadian Journal of Urology. 2009;16(2):4568-4575.

Introduction: Fracture of the penis is rare and needs a surgeon's attention for appropriate management. The exact role of diagnostic investigations has not been established. We studied the role of these investigations and the results of surgery.

Case series: Seventeen patients with median age of 36 years (range, 27-72 years) presented to us between 2002 and 2007 with suspected fracture of the penis. The mode of injury was sexual intercourse (15 patients), masturbation (1 patient), and rolling over in bed (1 patient). The median time from injury to presentation was 10 hours (range, 1-144 hours). Clinical evaluation included patient history and examination for all patients, ultrasonography in 6 patients, retrograde urethrography in 6 patients, and magnetic resonance imaging in 1 patient. Fifteen patients underwent immediate surgical exploration, 1 patient was kept under observation, and 1 patient refused surgical exploration.

Discussion: Patient history and clinical examination were highly sensitive and accurate in predicting a cavernosal tear, and retrograde urethrography was highly sensitive and accurate in detecting urethral injury. Ultrasonography was highly specific but not sensitive for detecting a cavernosal tear. Radiological investigations did not influence patient management in any of the cases. On surgical exploration, 15 patients had cavernosal tears and 4 also had urethral injuries; all injuries were repaired successfully. One patient had a negative surgical exploration and was diagnosed as having a superficial dorsal vein rupture. One patient had a history suggestive of penile fracture but had a normal clinical examination and was kept under observation. At follow up in a mean of 7.5 months, no patient had erectile dysfunction or penile deformity.

Conclusion: Further evaluation beyond taking a patient history and performing a clinical examination is not necessary in most cases for managing patients with suspected penile fracture. Retrograde urethrography may be omitted before surgical exploration, even in cases with suspected urethral injury. Early surgical repair is associated with a good outcome with minimal complications.

Key Words: penile erection, penile disease, ultrasonography, corpus cavernosum, urethrography, penile fracture, fracture of the penis

Accepted for publication November 2008

Address correspondence to Dr. Mayank Mohan Agarwal, Department of Urology, Level II, B Block, Advanced Urology Center, Nehru Hospital, Postgraduate Institute of Medical Education and Research, Chandigarh, India

Introduction

Fracture of the penis (*faux pas du coit*) is a rare urological emergency that was first reported by an Arab surgeon, Abul Kasem, in Cordoba over 1000 years

ago.¹ Although the true incidence of penile fracture is unknown, the reported incidence ranges from 1 in 175,000 hospital admissions in the United States² to 52 or more per year in a hospital in Kermanshah, Iran.³ The pathological lesion is a tear of the tunica albuginea of the corpus cavernosum with or without involvement of the corpus spongiosum and the urethra, resulting from trauma to the erect penis.

Various etiologies for penile fracture have been cited in the medical literature including bending during intercourse (which is most common in the Western world); masturbation; rolling over in bed during sleep; direct trauma; “taghaandan” (meaning to “click” or to “snap” in Kurdish), which is forced bending to achieve detumescence, industrial accidents, gunshot wounds, and other modalities.^{1,3-5,6} Typically, the patient hears a “click” that is followed by collapse of the erection with intense local pain and the formation of a hematoma with a characteristic “eggplant deformity” (blue discoloration and edema of the penis, with bending of the penis to one side). There is a palpable tunical defect and the tear can be identified in a clinical examination by means of a “rolling sign.” A “rolling sign” results from a clot trapped in a well localized position under Buck’s fascia, which is felt as a discrete, smooth, fixed, tender, firm lump at the ‘fracture’ site over which the penile skin may be rolled. These characteristics are considered pathognomonic.^{1,6,7} There may also be urethral bleeding or inability to void, indicating associated urethral injury.

Various radiological investigations — such as cavernosography,^{8,9} retrograde urethrography (RUG),^{6,10} ultrasonography (USG)^{1,8,11-13} and, recently, magnetic resonance imaging (MRI)^{8,14} — have been used to diagnose penile fracture. However, the sensitivity and specificity of each of these techniques are significantly different and none has proven to be the definitive clinical diagnostic tool. Although the use of conservative versus surgical patient management remains controversial, most recent patient series have favored the latter approach.^{1,6,8}

We evaluated the role of clinical assessment and radiological investigations in the diagnosis of penile fracture in 17 patients. We also looked at the outcomes of immediate surgical exploration.

Case series

From July 2002 to May 2007, 17 patients with a median age of 36 years (range, 27-72 years) presented to us with a history of blunt trauma to the erect penis, Table 1. The penile fractures had been sustained during sexual intercourse (15 patients), masturbation (1 patient), or rolling over in bed (1 patient). The median time from

injury to presentation was 12 hours (range, 1-144 hours). All patients reported a sudden onset of local pain followed by detumescence of the penis. Thirteen patients heard a “click” at the time of the event. Sixteen patients developed swelling and discoloration of the penis.

Urethral injury was suspected in 7 patients on the basis of blood at the meatus (5 patients), inability to void (5 patients), difficulty with urination (1 patient) and hematuria (1 patient). One patient presented 144 hours after the event, and another presented 100 hours after the event. The former patient complained of a sudden onset of pain during intercourse followed by slow detumescence and progressive swelling over 15 minutes. At presentation, the skin on the penis was edematous and excoriated. The other patient heard a sudden “click” and had intense pain, immediate detumescence, and penile swelling. By the time he presented, the swelling had subsided significantly, but a rotational penile curvature persisted.

Physical examination revealed a typical “eggplant deformity” in 14 patients, Figure 1, and the “rolling sign” was present in 7 patients. Diagnostic investigations included RUG (6 patients), USG (6), and MRI (1), and 10 patients had no diagnostic investigation before surgical exploration. Sixteen patients underwent surgical exploration, all under regional anesthesia.

The sensitivity, specificity, positive predictive value, and negative predictive value of presenting features, RUG, USG, and surgical exploration are summarized in Table 2.

Patient history and clinical examination were highly sensitive and accurate in predicting the presence of cavernosal tears.

RUG, which was performed on 6 patients, was a highly sensitive and specific test to detect urethral injury. RUG scans of 2 patients are shown in Figure 2. RUG findings did not change patient management strategy (based on clinical assessment) in 3 patients who underwent surgery or in 1 patient who was treated by conservative management. No missed urethral rupture was identified. In 4 patients, surgical exploration detected a urethral rupture that required repair.

USG, which was performed in 6 patients, was highly specific for the diagnosis of cavernosal tear but was not very sensitive. It also did not change patient management strategies (5 patients had surgery and 1 patient had conservative management). MRI was performed in only one patient (Table 1, patient no. 12). MRI was inconclusive in identifying this patient’s cavernosal tear, whereas USG demonstrated the cavernosal tear very well, Figure 3.

TABLE 1. Patient characteristics, presentation, and management

Pt. no.	Age (yrs)	Time of presentation (hrs)	External deformity	Suspicion of urethral injury	Rolling sign	Radiological investigation(s)	Repair (suture)
1	40	12	Eggplant deformity	-	+	-	Repair of tunica (3/0 vicryl)
2	32	8	Eggplant deformity	Inability to void, blood at meatus	-	USG-hematoma, RUG-extravasation and intravasation	Repair of tunica (2/0 vicryl) and urethra (3/0 vicryl)
3	43	10	Eggplant deformity	-	-	-	Repair of tunica (3/0 prolene)
4	33	6	Eggplant deformity	Difficulty in voiding, hematuria, blood at meatus	-	USG-hematoma, tear identified RUG- gross extravasation and intravasation	Repair of tunica (3/0 vicryl) and urethra (3/0 vicryl)
5	27	8	Eggplant deformity	Inability to void	-	USG- hematoma no tear RUG- no extravasation	Repair of tunica (3/0 prolene)
6	34	12	Eggplant deformity	Inability to void	+	RUG-no extravasation	Repair of tunica (2/0 vicryl)
7	28	48	Eggplant deformity	-	-	-	Repair of tunica (2/0 vicryl)
8	33	12	None	Blood at meatus	-	USG-no hematoma/tear RUG-intravasation of contrast in distal urethra	Conservative
9	42	144	Penile edema, excoriation, discoloration	-	-	-	Hematoma in Dartos fascia, no tunical tear
10	29	18	Eggplant deformity	Inability to void, blood at meatus	+	-	Repair of tunica (3/0 prolene) and urethra (3/0 vicryl)
11	51	1	Eggplant deformity	-	+	-	Repair of tunica (1/0 vicryl)
12	36	100	Mild edema, rotational curvature of penis	-	+	USG-hematoma, tear in tunica of right cavernosum MRI- hematoma, doubtful tear in right cavernosum	Repair of tunica (4/0 prolene)
13	44	2	Eggplant deformity	-	+	-	Repair of tunica (3/0 vicryl)

TABLE 1 (cont'd).

14	58	24	Eggplant deformity	Blood at meatus, inability to void	-	USG-no tear in tunica RUG-complete urethral extravasation	Repair of tunica (3/0 vicryl) and urethra (3/0 vicryl)
15	72	5	Eggplant deformity	-	+	-	Repair of tunica (3/0 vicryl)
16	30	4	Eggplant deformity	-	-	-	Repair of tunica (3/0 vicryl)
17	50	10	Eggplant deformity	-	-	-	Refused exploration

RUG = retrograde urethrography; USG = ultrasonography

Fifteen patients underwent immediate surgical exploration under regional anesthesia. All surgeries were done using a subcoronal degloving incision. A urethral catheter was placed only after the penis was degloved and the hematoma was evacuated. Corpus cavernosum tears were identified in 14 patients, and urethral injury requiring repair was found in 4 patients. Various suture materials, Table 1, were used to repair the corpora cavernosa without any problem on follow up. In one patient, surgery did not detect any corpus cavernosal tear (Table 1, patient no. 9). A careful retrospective examination of this patient's history revealed that he had not heard a "click" and detumescence was not immediate but was delayed by 15 minutes. The remaining 14 patients in which surgery identified a corpus cavernosal tear had experienced an immediate detumescence, and 9 patients had

heard a "click." Postoperatively, the patient without a cavernosal tear developed focal desquamation of the penile skin, which healed without intervention.

One patient was managed conservatively (Table 1, patient no. 8). He had a history of detumescence and urethral bleed following intercourse, but at the time of presentation, his clinical examination was essentially normal and he was able to void without difficulty despite evidence of spongiosal intravasation of contrast material in a RUG scan, Figure 2b. Active intervention such as urethral catheterization was not required in this case.

All patients remained potent at a mean follow up of 7.5 months (range, 3-24 months) and no long term complications or sequelae such as stricture or cordee were identified. The mean follow up of patients with urethral injury was 16.2 months (range, 12-24 months).

TABLE 2. Sensitivity, specificity, and predictive values of clinical history, physical examination, radiological investigations, and surgical exploration for suspected penile fracture

S. no.	Sensitivity (%)	Specificity (%)	PPV (%)	NPV (%)
Hearing of 'click'†	86.6	100.0	100.0	50.0
Immediate detumescence†	100.0	50.0	93.8	100.0
Eggplant deformity†	93.3	50.0	93.3	50.0
Rolling sign†	46.6	100.0	100.0	20.0
Combined 1-4†	100.0	100.0	100.0	100.0
RUG‡	100.0	100.0	100.0	100.0
USG†	50.0	100.0	100.0	25.0
Direct surgical exploration†	100.0	100	86.6	100.0

† = tunical tear in corpus cavernosum; ‡ = urethral injury; NPV = negative predictive value PPV = positive predictive value, RUG = retrograde urethrography, USG = ultrasonography

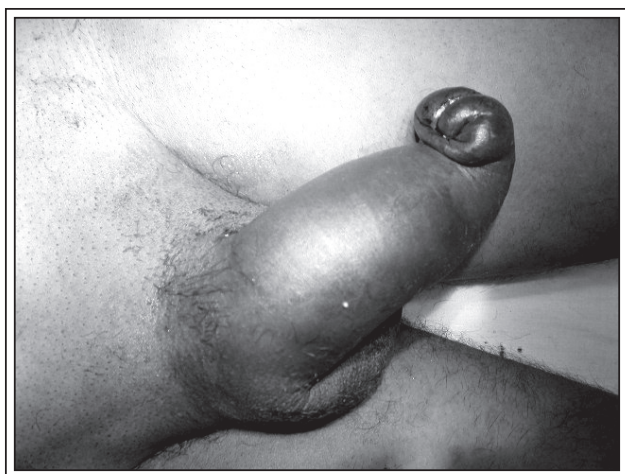


Figure 1. A typical “eggplant deformity” of the penis with blue-purple discoloration, swelling, and bending of the penis.

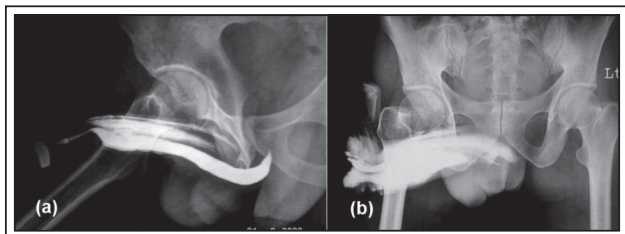


Figure 2. a. Retrograde urethrography (RUG) scan in a patient with blood at the meatus and inability to void at presentation; b. RUG in a patient with a history of urethral bleed and a normal physical examination.

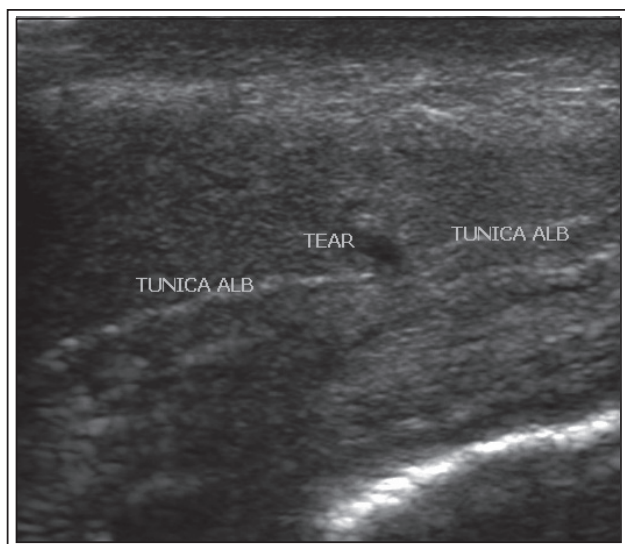


Figure 3. Ultrasonography (USG) scan in a patient with delayed presentation, which shows a tunical tear of the corpus cavernosum.

Discussion and literature review

We performed a ‘Pubmed’ and ‘Google Scholar’ search in the English medical literature using the keywords “fracture of the penis,” “penile trauma,” “urethral injury,” “retrograde urethrography,” “cavernosography,” “ultrasonography,” and “MRI penis fracture.”

Injuries to the penis are uncommon because of the well-protected location on the body and a high degree of genital mobility. Our series of 17 cases represented nearly 0.08% of all urological operations requiring anesthesia and 0.15% of all emergency calls we attended to from July 2002 to May 2007 at our institutions. The mechanism of penile injury is usually a direct blunt force that causes a sudden bending of the penis, which occurs most commonly during sexual activity or masturbation.^{1,3-5} Not surprisingly, men who are most commonly affected are in their 30s or 40s. However, penile injury has been reported in a wide range of ages from 12 to 82 years.^{1,3,6,9} Our cohort comprised of patients with median age of 36 years (range, 27-72 years), which falls in the reported age range.

It has been determined that during erection, the tunica albuginea is stretched and thins from 2 mm to 0.25 mm to 0.50 mm, and it may give way to a bending force that often generates pressures in excess of 1500 mm Hg.^{8,15}

Typically a patient reports hearing a sudden “clicking” sound and feels intense pain which is accompanied by penile swelling and immediate detumescence.^{1,6} The “click” has been variously reported as sounding like a “sharp crackle”,¹⁶ “breaking of a cornstalk”,¹⁷ or “breaking of a glass rod”,¹⁸ heard by the patient and/or his partner. This “clicking sound” is generally reported in more than 50% of cases of penile fracture.^{6,19} It was present in 86.6% of our cases, and its presence was highly suggestive of penile fracture (positive predictive value 100%).

Sudden detumescence is an important marker of penile fracture, and it is believed to occur due to the extravasation of blood and the presence of pain. A delay in detumescence suggests an intact corpora cavernosa, and in such cases, detumescence may be caused by pain and possibly a venous leak, as happened in one of our patients (Table 1, patient no. 9). Moreover, we found that immediate detumescence is a highly sensitive (100%) but non specific (50%) feature of penile fracture, and its absence can quite reliably rule out this diagnosis. Most of the published literature has reported that penile fracture is characterized by immediate detumescence; however, there are a few reports of continued intercourse after fracture.²⁰

Surgical exploration of the patient in our series without immediate detumescence could have been avoided, based on this clinical characteristic.

Clinically, patients with penile fracture may have a palpable gap or depression in the penile shaft. The 'rolling sign' is generally present in less severe cases when Buck's fascia is intact and may be obscured when blood is extravasated along the fascial planes into the scrotum and pubic areas due to tearing of Buck's fascia.⁶ In our series, this sign was highly specific and predictive of penile fracture, which agrees with the published literature.^{1,6,7}

Urethral injury is suspected on the basis of the presence of blood at the urethral meatus, voiding difficulty, inability to void, and hematuria. The reported incidence of urethral injury ranges from 0% to 3% in Japan and Persian Gulf countries to 20% to 38% in the United States and Europe.^{6,19,21,22} This difference may be due to the fact in the former countries, the penis was most commonly bent using a relatively weak force (taghaandan), whereas in the Western world, this occurred most commonly with sexual intercourse, which exerts a larger force. The 29.4% (5/17) incidence of urethral injury found in our case series, in which intercourse was the most common etiology, is consistent with the reported incidence in the literature. In fact, one patient in our series had isolated (partial) urethral injury that was managed conservatively (Table 1; patient no. 8; Figure 2b). Isolated urethral injury in this scenario is exceedingly rare²³ and has been rarely reported, even in large case studies.^{3,6,9}

Authors have suggested using USG, cavernosography, RUG, MRI, color Doppler duplex scanning, angiography, and urethroscopy to investigate suspected penile fracture. However, the usefulness of imaging in detecting cavernosal injury is debatable. The use of penile cavernosography remains controversial. Although some authors recommend routine cavernosography for all patients with suspected penile fracture,^{9,24} most suggest reserving it for unusual cases, such as those with delayed presentation or discrepancies in clinical findings.¹⁰ There is a significant incidence of false negative results (due to early sealing of the defect by a clot) as well as a risk of tissue reactions to contrast material and increased liability to corporal fibrosis.^{8,25} Therefore, even in doubtful cases, the clinical utility of cavernosography remains limited.

Penile USG is widely available and inexpensive. The findings of penile fracture on USG are well described. However, similar to cavernosography, USG is highly operator dependent and requires specific expertise.¹³ The rarity of penile fracture often

precludes wide experience and accurate diagnosis, and small albuginea disruptions or the presence of clots at the 'fracture' site may make diagnosis difficult.^{26,27} Therefore, false negative findings are common. In our series, penile ultrasonography was not very sensitive. It had a high negative predictive value and it did not change the management in any of the patients, suggesting that it has limited clinical utility.

Some authors have recommended that RUG be used for all patients with suspected penile fracture, whereas others recommend a more selective approach. Agarwal et al²⁸ recommend that RUG be performed in all patients with suspected penile fracture. Similarly, Miller and McAninch¹⁰ recommend that "only in the setting of an unremarkable urinalysis and the complete lack of voiding complaints... should one forego urethrography. This should be considered an exception rather than standard practice." However, most authors disagree with this statement and reserve this investigation for patients with a high suspicion of urethral injury — for example, patients with blood at the meatus or an inability to void.^{6,29} In fact, Karadeniz et al⁹ concluded that routine urethrography is unnecessary. We followed a selective approach and did not miss any case of urethral injury. Moreover, RUG findings did not change the treatment plan for any patient. One patient had an isolated urethral mucosal injury and was managed conservatively. Another patient had surgical exploration without RUG despite a clinical suspicion of penile fracture, because the emergency x-ray equipment was malfunctioning. After this patient's penis was degloved, he was catheterized, and the urethral injury was promptly recognized. All patients were managed intraoperatively in the same way, and urethral injury was recognized without difficulty. This suggests that the clinical utility of RUG is limited, because it is easy to recognize urethral injury intraoperatively. Intraoperative identification of such injury may further be facilitated by retrograde saline instillation into the urethra to look for any leakage from the urethra.

MRI is the most accurate diagnostic and localizing procedure in cases of penile fracture, owing to its multiplanar capabilities and good spatial and tissue contrast resolution.^{14,30,31} It undoubtedly gives high quality images and has been reported to improve the surgical plan by limiting the incision to a localized longitudinal one rather than the standard degloving one.¹⁴ But, MRI has severe limitations including time, availability, and significant cost. A typical case of penile fracture can generally be fairly accurately diagnosed clinically; adding MRI is not cost effective and can delay patient treatment. Moreover, localized

incision, which is considered the most significant clinical advantage of MRI, has been associated with poor cosmesis.^{1,28} However, MRI may be justified in atypical or equivocal cases when diagnoses other than fracture are being considered. We employed it in one patient who had a delayed presentation, but the interpretation of the MRI scan was inconclusive.

The management of penile fracture has undergone an evolution from a completely conservative approach^{20,32} to a selective surgical approach^{33,34} to a delayed surgical approach³⁵ to the currently acceptable immediate surgical exploration that is done for most patients.^{1,6,8} "Conservative" management consists of strategies such as ice-packs, Foley catheterization, anti inflammatory medicines, compression bandages, erection inhibiting estrogens, penis splints, antibiotics, and fibrinolytic agents.^{32,36} The complication rate with this approach is high (25% to 53%) and includes painful erections, severe penile angulation, arterial venous fistulas, infected hematomas, abscess formation, and impotence.^{36,37}

Surgical repair of penile fractures was popularized in the 1980s after several studies demonstrated that long term complications were reduced to 4% in surgically treated patients.³⁶⁻³⁸ Thus, the current literature generally advocates immediate surgical repair upon presentation to the hospital. In the event of a delayed presentation (48 hours or more after the injury), immediate repair is still advocated, although it is associated with increased risk of long term sequelae.¹⁹ Surgical management consists of evacuation of the hematoma, identification of the tunica injury, local corpora debridement, closure of the tunica lacerations, ligation of any disrupted vasculature, and urethral repair, if required. The most commonly employed and recommended incision is a degloving circumferential subcoronal incision, which is considered to have good cosmetic results and to be versatile.^{6,8,10} It readily allows exposure to the entire tunica bilaterally, facilitating diagnosis and repair of coexisting urethral and contralateral injuries.⁸ Other incisions — such as direct longitudinal, suprapubic, and perineal incisions — have also been reported, with attendant advantages and disadvantages.^{1,8,14,28} We employed the degloving incision in all our cases with good cosmetic results, and would continue to use this approach unless another approach was specifically indicated. Both absorbable and non absorbable sutures (with inverted knots) have been used in both an interrupted and a continuous fashion.^{6,35} We used both types of suture materials and did not find any difference in immediate or long term outcomes.

Despite the ability to obtain a stereotypical patient history and perform a reliable examination in most cases of penile fractures, negative findings are occasionally

encountered at the time of surgical exploration. Presumed penile fractures unaccompanied by rapid detumescence or those that lack the classic "click" sound are more likely to be negative on surgical exploration.³⁹ Reported etiologies that mimic penile fracture include rupture of the dorsal artery⁴⁰ and veins⁴¹ and rupture of the suspensory ligament of the penis.⁴² These so called negative surgical explorations are still useful in terms of evacuation of hematomas and ligation of ruptured vessels to prevent complications.²⁹ One patient in our series who underwent surgical exploration had a negative finding for penile fracture, with no hematoma beneath the Buck's fascia, and the wound was closed after proper toileting.

Based on our experience with this series of patients and a review of literature, we cannot over emphasize that even in the era of advanced radiological technology, a clinical history and patient examination are the most important tools in the diagnosis of penile fracture and are generally sufficient to make the diagnosis. Therefore, most patients can be diagnosed cost effectively and treated surgically without a need to delay surgery, which is often the case if one were to resort to other investigations. Investigations such as RUG for suspected urethral injury should only be used when the diagnosis of penile fracture is in doubt.

The small number of cases in our series and the rarity of this condition suggest that the clinical significance of diagnostic investigations should be further explored in large, multicenter studies.

Conclusion

Fracture of the penis is an injury that is easily diagnosable by taking a detailed and focused patient history and performing a careful physical examination. It rarely warrants further radiological investigations such as RUG, USG, Doppler, cavernosography, or MRI. RUG can be avoided even in cases of suspected urethral injuries, because these injuries can be easily recognized intraoperatively and skip lesions are exceedingly rare. Immediate surgical exploration and repair is the key to a good long term outcome for patients with penile fracture. □

References

1. Eke N. Fracture of the penis. *Br J Surg* 2002;89(5):555-565.
2. Farah N, Stiles R, Cerny JC. Surgical treatment of deformity and coital difficulty in healed traumatic rupture of the corpora cavernosa. *J Urol* 1978;120(1):118-120.

3. Zargooshi J. Penile fracture in Kermanshah, Iran: the long-term results of surgical treatment. *BJU Int* 2002;89(9):890-894.
4. Tan LB, Chiang CP, Huang CH, Chou YH, Wang CJ. Traumatic rupture of corpus cavernosum. *Br J Urol* 1991;68(6):626-628.
5. Fetter TR, Gartman E. Traumatic rupture of penis: a case report. *Am J Surg* 1936;32:371-372.
6. Zargooshi J. Penile fracture in Kermanshah, Iran: report of 172 cases. *J Urol* 2000;164(2):364-366.
7. Rosenstein D, McAninch JW. Urologic emergencies. *Med Clin N Am* 2004;88(2):495-518.
8. Jack GS, Garraway I, Reznicek R, Rajfer J. Current Treatment Options for Penile Fractures. *Rev Urol* 2004;6(3):114-120.
9. Karadeniz T, Topsakal M, Ariman A. Penile fracture: differential diagnosis, management, and outcome. *Br J Urol* 1996;77(2):279-281.
10. Miller S, McAninch JW. Penile fracture and soft tissue injury. In: McAninch JW, ed. *Traumatic and Reconstructive Urology*. Philadelphia: W.B. Saunders;1996:693-698.
11. Koga S, Saito Y, Arakaki N. Sonography in fracture of the penis. *Br J Urol* 1993;72(2):228-229.
12. Hoekx L, Wyndaele JJ. Fracture of the penis: role of ultrasonography in localization of the cavernosal tear. *Acta Urol Belg* 1998;66(1):23-25.
13. Bhatt S, Kocakoc E, Rubens DJ, Seftel AD, Vikram S, Dogra VS. Sonographic Evaluation of Penile Trauma. *J Ultrasound Med* 2005;24(7):993-1000.
14. Abolyosr A, Moneim AEA, Abdelatif AM, Abdalla MA, Imam HMK. The management of penile fracture based on clinical and magnetic resonance imaging findings. *BJU Int* 96(3):373-377.
15. Seaman EK, Santarosa RP, Walton GR, Katz AE. Immediate repair: key to managing the fractured penis. *Contemp Urol* 1993;5:13-21.
16. Pyror JP, Hill JT, Packham DA, Yates-Bell JA. Penile injury with particular reference to erectile tissue. *Br J Urol* 1981;53(1):42-46.
17. McKay HW, Hawes JA. Traumatic fracture of penis. *JAMA* 1935;105:1031-1032.
18. Thompson RF. Rupture (fracture) of penis. *J Urol* 1954;71(2):226-229.
19. Ishikawa T, Fujisawa M, Tamada H, et al. Fracture of the penis: nine cases with evaluation of reported cases in Japan. *Int J Urol* 2003;10(5):257-260.
20. Tiong JT, Taylor A, England E, Hirsch R. Fracture of the penis-review with a case report. *Aust N Z J Surg* 1988;58(5):428-431.
21. McDougal, W. S. Methods of care and special considerations of perineal genital wounds. In: *Reconstructive Urologic Surgery*, 3rd ed. Edited by J. A. Libertino. St. Louis: Mosby, 1998;chapt. 69, pp-653-660.
22. Asgari MA, Hosseini SY, Safarinejad MR. Penile fractures: evaluation, therapeutic approaches and long long-term results. *J Urol* 1996;155(1):148-149.
23. Cortellini P, Ferretti S, Larosa M. Traumatic injury of the penis: surgical management. *Scand J Urol Nephrol* 1996;30(6): 517-519.
24. Beyssel M, Tekin A, Gurdal M, Yceba E, Sengör F. Evaluation and treatment of penile fractures: accuracy of clinical diagnosis and the value of corpus cavernosography. *Urology* 2002;60(3):492-496.
25. Pliskow RJ, Ohme RK. Corpus cavernosography in acute 'fracture' of the penis. *AJR Am J Roentgenol* 1979;133(2):331-332.
26. Chung CH, Szeto YK, Lai KK. Fracture of the penis: a case series. *Hong Kong Med J* 2006;12(3):197-200.
27. Fedel M, Venz S, Andreessen R, Sudhoff F, Loening SA. The value of magnetic resonance imaging in the diagnosis of suspected penile fracture with atypical clinical findings. *J Urol* 1996;155(6):1924-1927.
28. Agrawal SK, Morgan BE, Shafique M, Shazely M. Experience with penile fractures in Saudi Arabia. *Br J Urol* 1991;67(6):644-646.
29. Morris SB, Anson K, Miller MAW. Management of penile fracture. *J R Soc Med* 1998;91(8):427-428.
30. Choi MH, Kim B, Ryu JA, Lee SW, Lee KS. MR imaging of acute penile fracture. *Radiographics* 2000;20(5):1397-1405.
31. Uder M, Gohl D, Takahashi M et al. MRI of penile fracture: diagnosis and therapeutic follow-up. *Eur Radiol* 2002;12(1):113-120.
32. Meares EMJ. Traumatic rupture of the corpus cavernosum. *J Urol* 1971;105:107-108.
33. Mydlo JH, Gershbein AB, Macchia RJ. Non-operative treatment of patients with presumed penile fracture. *J Urol* 2001;165(2):424-425.
34. Muentener M, Suter S, Hauri D, Sulser T. Long-term experience with surgical and conservative treatment of penile fracture. *J Urol* 2004;172(2):576-579.
35. Naraynsingh V, Raju GC. Fracture of the penis. *Br J Surg* 1985;72(4):305-306.
36. Nicoliasen GS, Melamud A, McAninch JW. Rupture of the corpus cavernosum: surgical management. *J Urol* 1983;130(5):917-919.
37. Wespes E, Libert M, Simon J, Schulman CC. Fracture of the penis: conservative versus surgical treatment. *Eur Urol* 1987;13(3):166-168.
38. Seaman EK, Santarosa RP, Walton GR. Immediate repair: key to managing the fractured penis. *Contemp Urol* 1993;5:13.
39. Shah DK, Paul EM, Meyersfield SA. False fracture of the penis. *Urology* 2003;61(6):1259.
40. Armenakas NA, Hochberg DA, Fracchia JA. Traumatic avulsion of the dorsal penile artery mimicking a penile fracture. *J Urol* 2001;166(2):619.
41. Nicely E, Costabile R, Moul J. Rupture of the deep dorsal vein of the penis during sexual intercourse. *J Urol* 1992;147(1):150-152.
42. Kropman RF, Venema PL, Pelger RC. Traumatic rupture of the suspensory ligament of the penis. Case report. *Scand J Urol Nephrol* 1993;27(1):123-124.