

BCG pyelonephritis following intravesical therapy for transitional cell carcinoma

Jorge E. Garcia, MD, David D. Thiel, MD, Gregory A. Broderick, MD

Department of Urology, Mayo Clinic Jacksonville, Jacksonville, Florida, USA

GARCIA JE, THIEL DD, BRODERICK GA. BCG pyelonephritis following intravesical therapy for transitional cell carcinoma. *The Canadian Journal of Urology*. 2007;14(2):3523-3525.

Bacillus Calmette-Guerin (BCG) is a common intravesical agent utilized for superficial transitional cell carcinoma of the bladder. The potential for side effects and complications does exist secondary to the utilization

of live attenuated bacteria. We present the case of a 70-year old male that developed BCG pyelonephritis and associated renal mass following the fifth of six weekly intravesical BCG therapies. The patient improved clinically and renal mass resolved following 3 months of isoniazid monotherapy without renal biopsy.

Key Words: bladder neoplasm, BCG, intravesical therapy

Introduction

Bacillus Calmette-Guerin (BCG) is the most commonly used intravesical therapy for superficial bladder carcinoma.¹ Since it is a live attenuated bacterium, the potential for complications exists. However, most complications are minor and self-limiting.² We present the rare case of BCG pyelonephritis associated with a renal mass in a patient following intravesical BCG therapy.

Case report

A 70-year old male was found to have a large bladder tumor overlying the left ureteral orifice following

evaluation for microscopic hematuria (seven red blood cells per high powered field). A CT scan/excretory urogram demonstrated normal kidneys and ureters with a bladder wall-filling defect. Figure 1a. Transurethral resection of bladder tumor was completed over the left ureteral orifice. No other tumors were identified in the bladder. Ureteral stent placed at the time of resection was removed after 21 days. Surgical pathology was consistent with high grade transitional cell carcinoma with lamina propria invasion (T stage 1, grade 3/3). Random bladder biopsies completed at the time of resection were negative for associated carcinoma *in situ*.

Past medical history was significant for type 2 diabetes, hypertension, and hyperlipidemia. The patient underwent weekly intravesical instillations of BCG beginning 4 weeks after tumor resection. Eighty-one milligrams of Tice strain BCG in 50 ml of normal saline was administered through a 16 french foley catheter and left in place for 2 hours. Following the fifth of six weekly instillations, the

Accepted for publication February 2007

Address correspondence to Dr. David D. Thiel, Mayo Clinic Jacksonville, 3 East Urology, 4500 San Pablo Road, Jacksonville, Florida 32224 USA

patient developed decreased appetite, malaise, and weight loss. The patient was afebrile but did have some mild left side flank pain and costovertebral tenderness. No leukocytosis was found. Urine cultures and blood cultures were negative without evidence of acid fast organisms. A subcutaneous PPD test was notable for induration within 24 hours of placement.

CT scan of the abdomen, Figure 1b and 1c, demonstrated a new heterogenous mass in the left

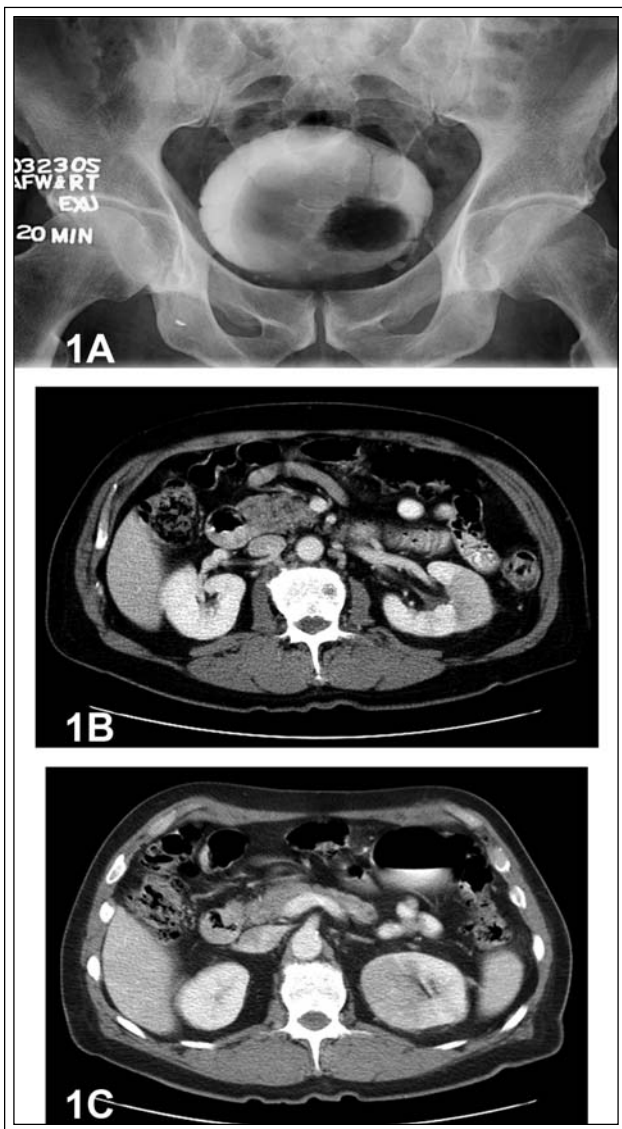


Figure 1. Excretory urogram of bladder lesion and CT scan of renal mass. a) Excretory urogram demonstrating the filling defect in the left wall of the bladder consistent with bladder tumor. b) CT scan demonstrating left sided heterogenous renal mass. c) Left renal mass demonstrating contrast enhancement.

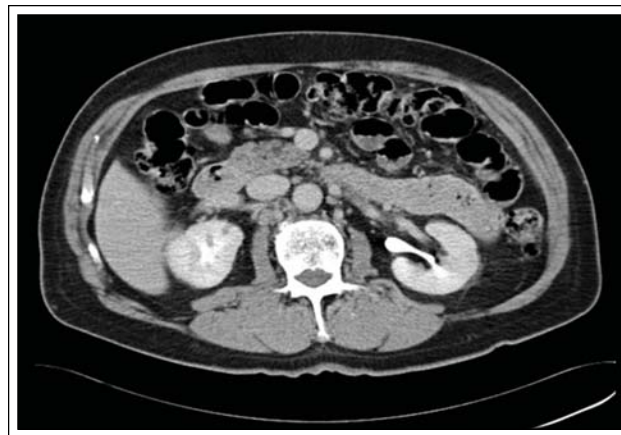


Figure 2. Follow-up CT scan following INH therapy. CT scan acquired 5 months from Figure 1 CT scan demonstrates almost complete resolution of renal mass.

kidney. The patient was placed on isoniazid (INH) and clinical improvement was noted within 2 days. INH was continued for 3 months. A follow-up CT scan 5 months later, Figure 2, demonstrated almost complete resolution of the lesion.

The sixth course of BCG was not administered. Repeat bladder biopsies 3 months following BCG completion were negative for carcinoma. Cystoscopic evaluation of the resected left ureteral orifice acquired during the repeat bladder biopsy is present in Figure 3. The patient is without bladder tumor recurrence for over 1 year.

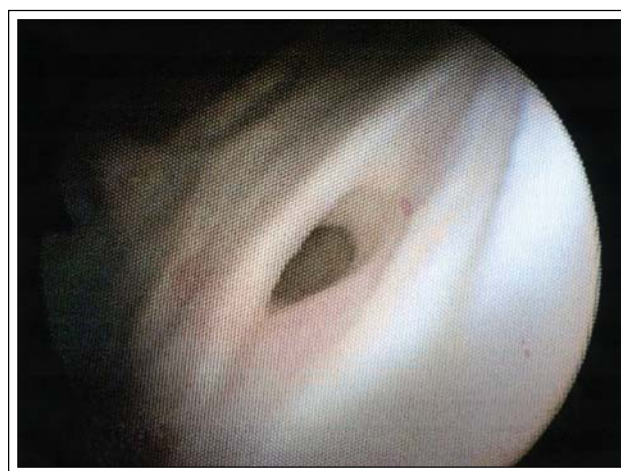

Figure 3. Appearance of resected left ureter on follow-up cystoscopy. Cystoscopic appearance of left ureter orifice during repeat biopsy. Note open appearance consistent with vesicoureteral reflux.

Discussion

Bacillus Calmette-Guerin (BCG) is the most effective agent for the treatment and prevention of superficial bladder cancer recurrence.¹ Intravesical BCG has demonstrated recurrence and progression free rates for high grade T1 transitional cell carcinoma of the bladder superior to resection alone, especially if maintenance protocols are utilized.^{3,4} Lack of tumor multifocality and associated carcinoma *in situ* made this patient a candidate for bladder sparing intravesical BCG therapy. However, BCG is a live-attenuated strain of Mycobacterium bovis so there are definite risks for complications.² Most side effects are mild and self-limiting but hematogenous absorption of the bacillus can lead to severe and sometimes fatal reactions.¹

Renal manifestations of intravesical BCG include interstitial nephritis, granulomatous masses, and ureteral strictures.⁵ Three reported cases of "BCG pyelonephritis" are present in the literature.⁵⁻⁷ A 66-year old male developed progressively worse symptoms following each of six intravesical BCG treatments. Despite clinical improvement on daily isoniazid (INH), the patient died from a myocardial infarction during his third day of hospitalization.⁶ Acid fast organisms were seen in the kidneys on autopsy.

A 51-year old male developed fever and flank pain immediately following his first intravesical BCG treatment 1 month after tumor resection.⁷ A heterogenous mass seen on CT scan was aspirated but failed to demonstrate evidence of acid fast organisms. The patient's symptoms resolved following a six-week course of (INH), rifampin, ethambutol, and prednisone. A third case involved a 63 year old male that developed fevers, sweats, and malaise following the first dose of BCG into an ileal conduit for upper tract transitional cell carcinoma.⁵ CT guided aspiration of a renal mass was notable for granulomas containing multinucleated giant cells. The patient's symptoms also resolved following 6 months of INH, rifampin, ethambutol, and pyrazinamide.

All three of the patients above had cystographic evidence of vesicoureteral reflux. We suspect reflux to be the etiology of our patient's pyelonephritis given the tumor resection over the ureteral orifice and post-resection cystoscopic appearance of the ureteral orifice. Some authors propose that patients with vesicoureteral reflux should be placed on prophylactic INH before intravesical administration of BCG.⁶ This seems unwarranted given the low rate BCG renal complications compared to the high incidence of reflux noted following bladder tumor resections.

A 1989 study noted that 237 of 899 patients had reflux following transurethral bladder tumor resection.^{6,8}

Two of the three previous reported cases had CT scan evidence of relatively large heterogenous renal masses similar to our patient. Percutaneous aspiration or biopsy of this mass was not attempted due to its temporal relation to BCG administration and failure of acid fast organism identification in previous cases.^{5,7} The renal mass resolved and the patient improved clinically following INH monotherapy for 3 months.

This report demonstrates that intravesical BCG can cause pyelonephritis and suspicion should be high in any patient with known or suspected vesicoureteral reflux (congenital or subsequent to bladder tumor resection). Percutaneous biopsy was not necessary in this case and rarely adds information that will alter treatment planning. INH monotherapy is sufficient if the patient is without clinical signs of vascular instability. □

References

1. Lamm DL, Stogdill VD, Stogdill BJ, Crispen RG. Complications of bacillus Calmette-Guerin immunotherapy in 1278 patients with bladder cancer. *J Urol* 1986;135:272-274.
2. Huang TC. Management of complications of bacillus Calmette-Guerin immunotherapy in the treatment of bladder cancer. *Ann Pharmacother* 2000;34:529-532.
3. Evans CP, Busby JE. The management of stage T1 grade 3 transitional cell carcinoma of the bladder. *BJU Int* 2003;92:345-348.
4. Herr HW, Schwalb DM, Zhang ZF et al. Intravesical bacillus Calmette-Guerin therapy prevents tumor progression and death from superficial bladder cancer: ten-year follow-up of a prospective randomized trial. *J Clin Oncol*. 1995; 13:1404-1408.
5. Squires FB, Coakley FV, Berg WJ, Panicek DM. Bilateral renal masses after local Bacillus Calmette-Guerin therapy for postcystectomy ureteral cancer. *Abdom Imaging* 1999;24:200-201.
6. Gonzalez JA, Bogdan RM, Wolf MC. Complications of intravesical bacillus Calmette-Guerin: A case report. *JUrol* 1992;148:1892-1893.
7. Boisgisson Ph DE, Roussel F, Leclerc D, Picquenot JM. Granulomatous renal mass during endovesical BCG therapy for bladder carcinoma. *Urology* 1991;37:557-560.
8. Mazeman E, Gilliot P. Vesicorenal reflux and intravesical chemotherapy. *Prog Clin Res* 1989;303:517- 522.