

# *Multiple bilateral Perivascular Epithelioid Cell Tumor (PEComa) of the kidneys*

Rahuldev Bhalla, MD, David Dail, MD, Paul Kozlowski, MD, John Corman, MD

Section of Urology & Renal Transplantation, Virginia Mason Medical Centre, Seattle, WA

---

BHALLA R, DAIL D, KOZLOWSKI P, CORMAN J. Multiple bilateral Perivascular Epithelioid Cell Tumor (PEComa) of the kidneys. *The Canadian Journal of Urology*. 2004;11(3):2296-2298.

*Perivascular Epithelial Cell (PEComa) Tumors are extremely rare. These tumors are often regarded as low grade Sarcomas and treated as such. We report a case of a 70 year old female with a history of nonspecific complaints and on routine CT scan had bilateral multiple*

*renal masses with no other extra renal disease. The largest mass on the right was 11 cm x 7 cm x 11 cm and the left there were multiple smaller masses. She underwent a right radical nephrectomy that showed a PEComa and an adjacent renal cell carcinoma. Her contralateral kidney was followed for 3 years with no evidence of growth or metastasis.*

**Key Words:** perivascular epithelioid cell, PEComa, kidneys

---

Accepted for publication March 2004

Address correspondence to John M.Corman, MD, Section of Urology & Renal Transplantation, Virginia Mason Medical Centre, PO Box 900, Seattle, WA 98111 USA

## Introduction

Perivascular Epithelial Cell (PEComa) Tumors are rare neoplasms of the kidney that are typically solitary and

## Multiple bilateral Perivascular Epithelioid Cell Tumor (PEComa) of the kidneys

benign. Bonetti et al first described this lesion in 1992 and since that time the classification has gained acceptance in the literature<sup>1</sup> The family of lesions comprising PEComa are thought to be composed of epithelioid cells that stain HMB-45 positive, keratin and mostly vimentin negative. Rare cases of renal PEComa have been described. To our knowledge this is the first case of multiple bilateral disease of the kidneys.

### Case report

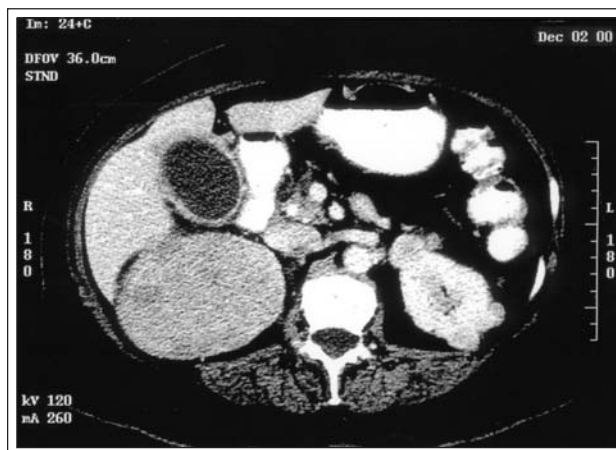
A 70 year-old female presented with complaints of nausea, vomiting, and weight loss. On cross sectional body imaging studies, she was noted to have multiple bilateral enhancing renal masses. The right renal mass was 11 cm x 7 cm x 7 cm and was consistent with renal cell carcinoma by CT scan criteria Figure 1. The left kidney showed multiple peripheral lesions, which were also consistent with renal cell carcinoma. There was no renal vein involvement. She denied flank pain, gross hematuria or systemic symptoms. She underwent an uncomplicated right radical nephrectomy.

Grossly, the right kidney contained multiple white nodular masses, (the largest being 12.5 cm x 7.5 cm. x 7.5 cm. Figure 2. Microscopically, epithelioid and spindle bland cells with abundant collagen bundles were present. No fat or significant vascular components were noted. Immunohistochemically, the tumor cells stained HMB-45 and smooth muscle actin positive, focally vimentin positive at growing edges of tumor and negative S-100 and low molecular weight cytokeratin BH11. There was also an incidental finding of a small focus (0.6 cm) of grade I/IV clear cell adenocarcinoma with negative margins.

The patient has been followed for 3 years with serial CT scans that show no interval growth or spread of disease. The patient has not reported any hematuria or flank pain in that period of time.

### Comment

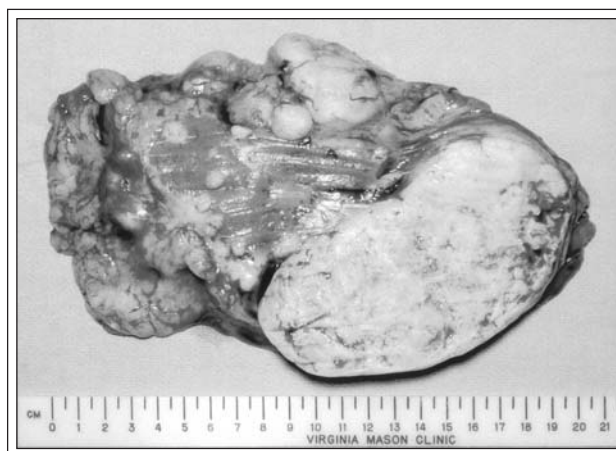The perivascular epithelioid cell has been proposed to be the unifying proliferating cell type in angiomyolipoma.<sup>3</sup> Epithelial tumors of the kidney have been reported to overlap with the Tuberous Sclerosis Complex. This patient had none of the classic features of Tuberous Sclerosis, although she does have bilateral epithelial tumors. Radiographically, PEComas can mimic renal cell carcinoma by contrast enhancement.



**Figure 1.** Large right renal mass with multiple smaller left enhancing renal masses.

Perivascular Epithelioid Cell tumor is a neoplasm composed of HMB-45 positive epithelioid cells with clear to granular cytoplasm with a perivascular distribution. There is a female predominance for PEComas (21:2) with a reported age range of 3 to 75 years old.<sup>2</sup>

These lesions are uncommon and in general have a benign course although some authors regard this as a low grade Sarcoma.<sup>2</sup> In addition, a small focus of clear cell adenocarcinoma (Grade I/IV) was located adjacent to the PEComa. For these reasons, this patient is being followed closely with serial CT scans of her abdomen and pelvis every 6 months for the past 3 years. There has been no interval growth of the renal masses in the contralateral kidney. The patient's renal function remains stable with a creatinine of 1.2 mg/dl.



**Figure 2.** Gross specimen of the right kidney with multiple nodules.

Perivascular epithelioid tumors are extremely rare and the precise tumor biology is unknown. We present a case of presumed bilateral renal involvement by PEComas. The patient has been followed for 3 years and is without evidence of recurrence or radiologic progression. One might consider following patients with histologically proven PEComa although the possibility of underlying malignancy (as in this patient) must be considered. □

---

#### References

---

1. Bonetti F, Pea M, Martignoni G et al. PEC and sugar. *Am J Surg Pathol* 1992;16:307-308.
2. Pan CC, Yang AY, Chiang H. Malignant Perivascular Epithelioid Cell Tumor Involving the Prostate. *Arch Pathol Lab Med* 2003;127(2):e96-98.
3. Bonetti F, Martignoni G, Colato C et al. Abdominopelvic Sarcoma of Perivascular Epithelioid Cells. Report of Four Cases in Young Women, One with Tuberous Sclerosis. *Mod Pathol* 2001;14(6):563-568.