

How I Do It: Hydrogel spacer placement in men scheduled to undergo prostate radiotherapy

Juan Montoya, MD, Eric Gross, MD, Lawrence Karsh, MD

The Urology Center of Colorado, Denver, Colorado, USA

MONTOYA J, GROSS E, KARSH L. How I Do It: Hydrogel spacer placement in men scheduled to undergo prostate radiotherapy. *Can J Urol* 2018; 25(2):9288-9293.

Hydrogel spacer placement between the prostate and rectum in men scheduled to undergo prostate radiotherapy is an emerging technique well suited for urologists. The hydrogel spacer reduces rectal injury during radiotherapy

by displacing the rectum away from the high dose region. Following radiotherapy the hydrogel spacer then liquifies, is absorbed, and then clears via renal filtration in approximately 6 months. Herein we describe the appropriate patients eligible for this procedure, and the application technique we use in our clinic.

Key Words: prostate cancer, radiotherapy, hydrogel spacer, application, quality of life

Introduction

Prostate radiotherapy is an accepted modality for the treatment of prostate cancer. Despite significant advances in technology, patients continue to frequently experience long term complications following prostate radiotherapy. For example, three recent prospective clinical trials found late Grade 2+ GI toxicity rates ranging from 14% to 25% in the 3-5 years following conventional prostate radiotherapy.¹⁻⁴ Due to radiation sensitivity and proximity to the prostate, the rectum is referred to as the primary organ at risk (OAR) in

prostate radiotherapy. This anatomical proximity can result in rectal toxicity and a decline in bowel-related quality of life. This proximity can also limit radiotherapy utilization in patients who experience a recurrence following prior radiotherapy, and in patients with inflammatory bowel diseases such as Crohn's disease or ulcerative colitis.

The ability to temporarily displace the rectum out of the high-dose radiation field surrounding the prostate could improve conventional radiotherapy. It could also enable radiation dose escalation, hypofractionation and salvage radiotherapy. This may result in safer delivery of radiation for patients with bowel issues who may otherwise be precluded for therapy, Figure 1. SpaceOAR System (Augmenix Inc, Bedford, MA, USA) is the only product approved as a prostate-rectum spacer in the United States, Canada, Europe, Australia and Japan. The spacer is placed via a transperineal injection of liquid hydrogel

Accepted for publication March 2018

Address correspondence to Dr. Juan Montoya, The Urology Center Of Colorado, 2777 Mile High Stadium Circle, Denver, CO 80211 USA

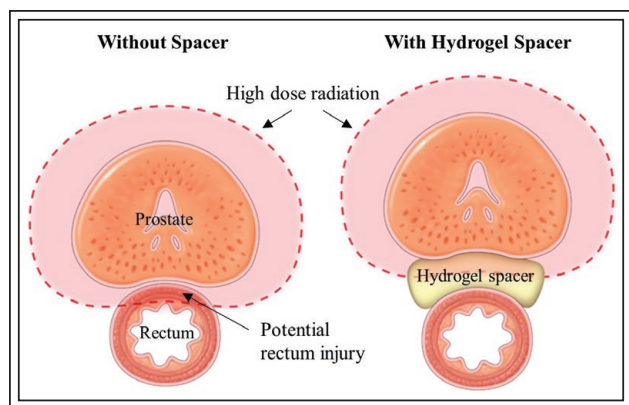


Figure 1. Prostate radiotherapy typically results in some anterior rectal wall exposure to high radiation dose (left). Hydrogel spacer displaces the rectum away from the prostate during radiotherapy, thus reducing radiation injury and long-term side effects (right). Courtesy of Augmenix Inc.

precursors, Figure 2, into the fat plane between Denonvilliers' fascia and the anterior rectal wall. Once injected the liquid expands the potential space and then solidifies within 10 seconds, forming an absorbable hydrogel spacer. Consisting primarily of water and polyethylene glycol (PEG), the SpaceOAR hydrogel chemistry is similar to other products used for surgical sealing and hemostasis.⁵⁻⁸ The hydrogel is designed to remain dimensionally stable for 3 months and liquify within 6 months via hydrolysis, followed by absorption, with final clearance via renal filtration.

The SpaceOAR hydrogel spacer was evaluated in a prospective, randomized, patient-blinded clinical trial with 37-month follow up.⁹⁻¹¹ For men randomized to the Spacer arm, spacer application had a 99% technical success rate, and the average 1.3 cm space created resulted in 97.5% of Spacer patients meeting the

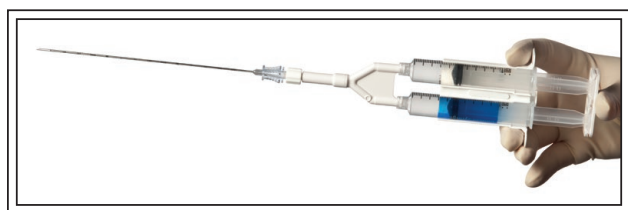


Figure 2. The SpaceOAR System applicator consists of two liquids that when injected into Denonvilliers' space polymerize into a hydrogel and create about 1 cm of space. The hydrogel persists for 3 months during prostate radiotherapy, and is then absorbed and cleared via renal filtration. Courtesy of Augmenix Inc.

prespecified rectal dose reduction endpoint. Using either general, local or MAC anesthesia the spacer application was well-tolerated by patients with a 10% rate of Grade 1 or Grade 2 transient procedure-related adverse events. The reduction in rectal radiation dose resulted in the elimination of late grade 2+ rectal toxicity in the Spacer arm relative to controls (0% versus 5.7%; $p = 0.012$). From 6-months onward the Spacer arm bowel QOL was at or near baseline, while the Control arm QOL was significantly less ($p = 0.002$). At 37 months 41% of Control men were experiencing a half-standard deviation decline in bowel QOL (defined as Minimally Important Difference or MID, which in bowel QOL = 5 points), compared to 14% of men in the Spacer arm ($p = 0.002$).

In addition to the prostate, rectum and bladder, the radiation dose to the penile bulb (bulb of the corpus spongiosum penis) was also calculated in each radiation plan. While dose to the penile bulb may not directly impact erections, prior studies suggest it may act as a surrogate for other yet to be determined structure(s) that are critical to erectile function.¹² In the trial the median penile bulb radiation dose was significantly reduced in the Spacer arm relative to Control (10.8 Gy versus 21.1 Gy, $p = 0.036$).¹³ At 37-months 53% and 75% ($p = 0.064$) of baseline potent Spacer and Control men were experiencing MID (11 points for sexual) declines in sexual QOL. Of these men 37.5% of Control and 66.7% of Spacer patients reported retaining "erections sufficient for intercourse" at 37-months ($p = 0.046$).

Our institution participated in the randomized clinical trial, and we are now using the spacer hydrogel in our eligible prostate radiotherapy patients. We will now describe our technique for application of the hydrogel spacer in an office setting with local anesthetic.

Method and technique

Equipment

Hydrogel spacers should only be applied via a transperineal approach to avoid the infection risk inherent in a transrectal approach. The hydrogel spacing procedure was refined in a European pilot clinical trial in which hydrogel spacer was transperineally applied using either a hand-held endfire transrectal ultrasound (Cohort 1, 15 mL hydrogel, $n = 23$), or with stepper mounted side-fire transrectal ultrasound (Cohort 2, 10 mL hydrogel, $n = 29$).¹⁴ In Cohort 1, three subjects (13%) experienced procedure-related adverse events. These included focal rectal mucosal necrosis caused by inadvertent injection of hydrogel into the rectal

wall in one patient, bladder injection in another and urinary retention in a third patient. These events all resolved with no further sequelae. In contrast, none of the patients (0%) in Cohort 2 experienced a device or procedural related event. Thereafter, the transperineal Cohort 2 procedure (stepper mounted side-fire probe, 10 mL injection) was used in the 149 US Pivotal study spacer patients with excellent results. We believe the Cohort 2 brachytherapy equipment (typically without a template) frees up both hands and allows for a more stable image which significantly increases the safety of hydrogel spacer implantation.

Patient selection

SpaceOAR hydrogel is indicated to temporarily position the anterior rectal wall away from the prostate during radiotherapy and facilitates all types of prostate radiotherapy. Special care should be taken when considering hydrogel spacer use in the rare patient with posterior extracapsular extension through Denonvilliers’ Fascia in order to avoid pushing cancer cells away from the radiation field. Additionally, caution is warranted in cases involving prior radiotherapy, prostatectomy, infection, cryotherapy, and TURP since fibrosis may prevent expansion of the perirectal space. Other potential contraindications include spacer use in patients with perirectal abnormalities such as fistula, as well as active inflammatory or infectious processes involving the perineum, gastrointestinal or urinary tract. Caution is recommended in patients with underlying comorbidities (e.g. cardiac disease, pulmonary disease, etc.) or with coagulopathies, inherent or medication induced.

Patient preparation

Standard pre procedure precautions for patients on aspirin or other blood thinners should be taken per individual institution protocol.

In the SpaceOAR Pivotal study 95% of patients received prophylactic antibiotics, and 0/149 Spacer patients had implant site infections. Our center prescribes a Levofloxacin 500 mg PO to be taken 2 hours prior to the procedure.

The day of the procedure each patient is instructed to eat a light breakfast, administer a Fleet enema 2 hours prior to procedure, and pre medicate with 5 mg-10 mg PO Valium as well as 5/325 mg Percocet 1 hour prior to procedure. Our policy is to make sure patients are accompanied by a responsible adult or have transportation arranged because patients are prohibited from driving after receiving these medications.

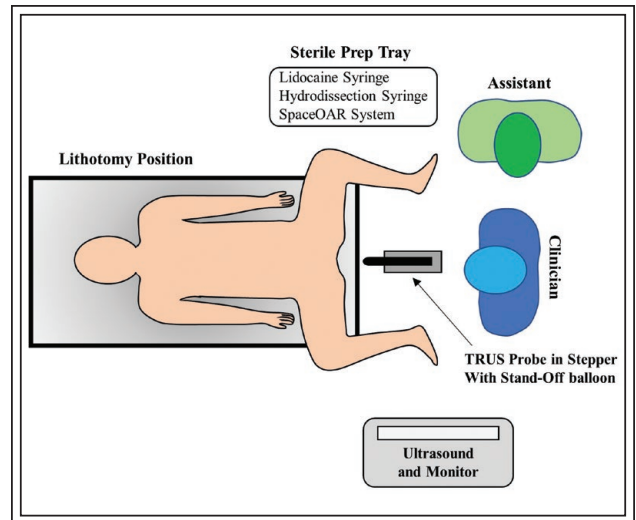


Figure 3. Illustration of typical room set up with patient in lithotomy position. Courtesy of Augmenix Inc.

Procedure

The patient is placed in the dorsal lithotomy position with stirrups used for leg retraction. Knees should be bent at 90° with anterior tibias parallel to the bed, see Figure 3. The scrotum is held away from the perineum with a medium sized Ioban drape. Emla (lidocaine 2.5% and prilocaine 2.5%) cream is applied to the perineum at least 30 minutes prior to aseptic skin preparation using Chlorhexidine. A sterile field is used to prepare 1) a 20 mL 2% lidocaine HCL syringe (without epinephrine) with 8.4% Sodium Bicarbonate (10:1) and a 22G x 6 inch spinal needle, 2) a 10 mL hydrodissection (HD) syringe (sterile saline) with the 18G x 15 cm needle from the SpaceOAR kit, and 3) the SpaceOAR hydrogel applicator (see package insert for preparation instructions).

The transrectal ultrasound (TRUS) probe is then prepared with a saline filled standoff balloon (using special care to avoid air bubbles) or condom. The probe is inserted and aligned appropriately from base to apex directly over the crystal, allowing an initial survey of the anatomy. It is very important to ensure optimal visualization by clearing any artifact present prior to continuing the procedure. The applicator then dons new sterile gloves and the probe and stepper are sterile draped.

Lidocaine is injected locally to anesthetize the perineum. The initial injection includes a subcutaneous “wheal” prior to advancing the needle into the deeper tissues. Depending on the size and sensitivity of the patient, we use 5 mL-20 mL lidocaine. The same needle is used to identify the midline as a reference point for HD of Denonvilliers’ space.

Preparing the SpaceOAR applicator after lidocaine infiltration provides sufficient time for local anesthesia to take effect prior to proceeding with fiducial marker insertion and spacer application.

Fiducial markers are placed via the transperineal route. Our preference is to place three markers to allow for triangulation of the prostate: one at the lateral base and another at the apex of the gland, with the third marker placed at mid-gland on the opposite lateral side.

The 18G HD needle should be primed with saline prior to insertion to prevent introduction of air, and the TRUS probe is placed caudally in the sagittal view to identify needle advancement. The HD needle is then advanced transperineally at a 10%-15% downward angle approximately 1.5 cm anterior to the TRUS probe through the midline, Figure 4A-4B. The needle tip (bevel down) is positioned over the rectal "hump", and is then advanced into Denonvilliers' space until it is positioned within the mid gland fat plane between Denonvilliers' fascia (DF) and the Anterior Rectal Wall (ARW), Figure 4C. Switching to the axial view, the needle tip is located and confirmed to be aligned in the prostate midline. Very slight needle tip movements confirm the needle tip is correctly positioned in the fat plane between the ARW and DF. A 1 cc saline "puff" injection demonstrates lateral distribution of saline which confirms proper needle tip positioning, Figure 4D. After the 1 cc saline injection puff confirms the appropriate location, further HD in the sagittal plane opens the space and will ensure adequate distribution of the hydrogel spacer from the base to apex, Figure 4E. If the initial saline puff reveals improper positioning, the needle can be readjusted and a 1 cc saline puff can be repeated. Viewing the mid gland needle tip in axial view confirms midline needle positioning with bilateral saline distribution, Figure 4F. Greater than 10 mL is rarely used for HD.

Probe positioning (height, angle, midline alignment) can influence hydrogel distribution, as illustrated in Figure 5. Therefore, taking time to reduce anterior

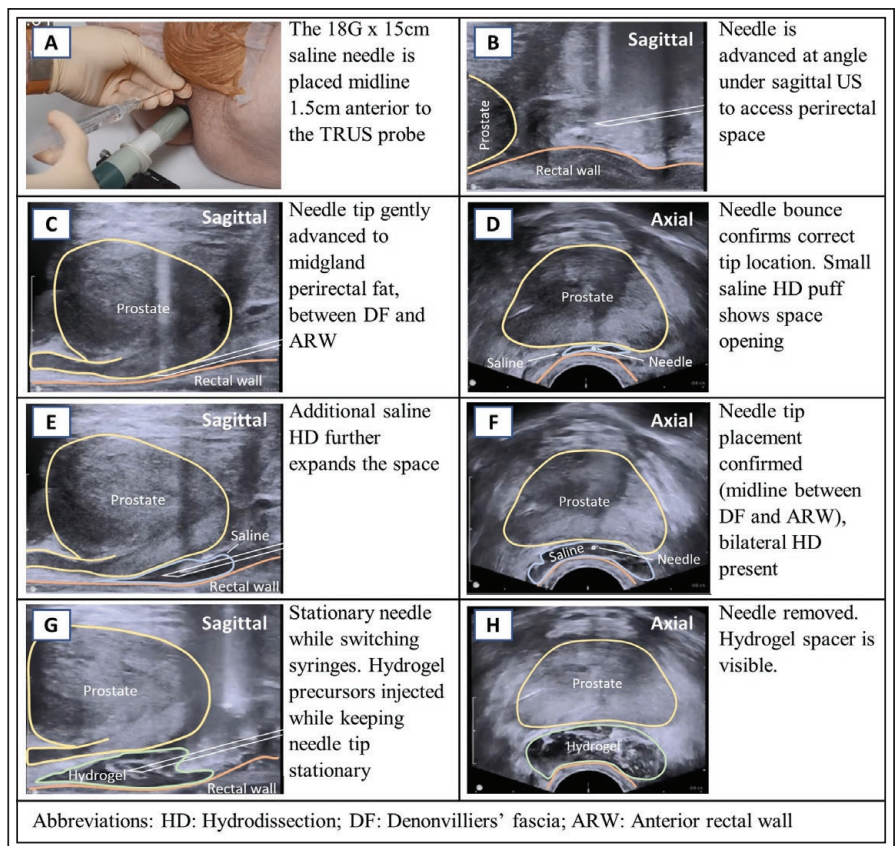


Figure 4. Transperineal hydrogel spacer placement using transrectal ultrasound probe. Needle placement. See procedure text for application steps. Courtesy of Augmenix Inc.

prostate compression and ensure proper probe angle can insure proper distribution of the hydrogel spacer.

Aspiration of the saline syringe is then performed to ensure the needle tip is not in an intravascular space. While holding the needle hub with one hand, the saline syringe is removed and the SpaceOAR hydrogel applicator is attached. Taking care not to move the needle while in the sagittal view, the hydrogel spacer is injected in one continuous motion over 8-10 seconds, Figure 4G. Starting and stopping during hydrogel injection will result in applicator and needle plugging, necessitating replacement of both the SpaceOAR applicator and the 18G needle. Following spacer injection, the needle can be immediately removed and the resulting spacer can be assessed in the axial view, Figure 4H.

Of note, bubbles may be introduced with the hydrogel, resulting in compromised prostate visibility immediately following spacer application. While these bubbles are transient and pose no safety risk, they can compromise prostate visibility if brachytherapy is performed after the hydrogel spacer application. Because of this potential artifact, LDR seed or HDR

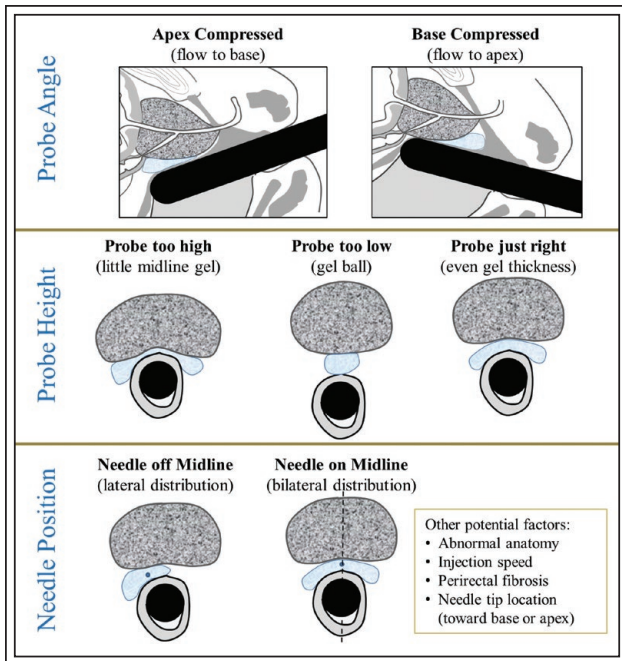


Figure 5. The TRUS probe in the rectum can act as a mold around which the hydrogel spacer forms. Therefore, the probe height, angle and alignment can significantly impact the resulting hydrogel distribution. Courtesy of Augmenix Inc.

catheter placement typically takes place before spacer application. Helpful tips for proper hydrogel spacer placement, see Table 1.

TABLE 1. Helpful tips for proper hydrogel spacer placement

Helpful tips

1. Do not perform this procedure transrectally. Use only steppor mounted side-fire TRUS probes.
2. Prepare the SpaceOAR kit between lidocaine injection and fiducial marker placement to allow time for anesthetic effect.
3. Do not prime the SpaceOAR applicator during assembly to avoid plugging.
4. Prime the 18G hydrodissection needle with saline before use to prevent air injection and US image degradation.
5. Use repetitive axial views and view slight needle tip movement to ensure needle tip is on the prostate midline and not in the rectal wall or anterior to Denonvilliers’ fascia.
6. Small saline puffs can be used to verify the needle tip is in the correct plane, and to determine if fibrosis prevents the perirectal space from opening.
7. If the perirectal space does not open during hydrodissection then fibrosis is likely present, and SpaceOAR hydrogel should not be injected.
8. Abandon spacer injection if any needle (anesthetic or hydrodissection needle) has entered the rectal lumen during the procedure.
9. Adjust TRUS probe height, angle and alignment prior to spacer injection to improve hydrogel distribution.
10. If the applicator or needle plugs during spacer injection note the amount injected, remove needle and applicator, prepare new kit and inject additional hydrogel to make 10 mL total.

Discussion

The SpaceOAR manufacturer mandates certification for all prospective users. Our experience suggests that physicians with prior transperineal and brachytherapy experience become proficient with this procedure quickly. Pinkawa et al compared the first 32 and second 32 patients treated in his facility. He found that while patients in the first group had significant rectum radiation protection, patients in the second group had even better hydrogel symmetry, space creation, and rectum dose reduction which resulted in less treatment-related acute rectal toxicity.¹⁵

Fischer-Valuck et al evaluated hydrogel distribution and incidence of rectal wall hydrogel infiltration in the spacer-treated men in the SpaceOAR US Pivotal study.¹⁶ Of the 149 men treated, spacer midline symmetry was noted in 71 (47.7%) patients, while the remaining 78 (50.9%) patients had some level of asymmetry, only 2 (1.3%) of which had far lateral spacer distribution (>2 cm). Although asymmetry was found to reduce the protection benefit, all patients but the two (1.3%) with the most asymmetrical placement still experienced significant rectal dose reduction ($p < 0.05$). Additionally, these researchers found that 9/149 (6.0%) patients had some amount of hydrogel infiltration into their rectal wall. These patients however did not have an increased rate of procedure-related adverse events or acute/late rectal toxicity relative to patients without rectal wall infiltration. Significantly, all “training” patients in the US study were included in the final study results.

Therefore, these asymmetry and rectal wall infiltration results were obtained in the first patients treated at the 20 participating centers. With experience, it is reasonable to assume that spacer application results will improve beyond the results which have been published to date.

To date we have injected SpaceOAR hydrogel in 125 patients. We find that the procedure is readily performed and tolerated by patients with minimal sedation and local anesthesia in the office setting. The procedure can be performed efficiently in a urology office procedure room.

Conclusion

Hydrogel spacer application is a procedure with a high success rate and very low risk for adverse reactions. Spacer presence during radiotherapy significantly reduces rectum and penile bulb radiation injury, resulting in significant reductions in late rectal toxicity, and improvements in bowel and sexual quality of life. We believe this procedure fits perfectly within the skill set of urologists, and can be performed safely and easily in an office, ambulatory surgical center or hospital setting.

Disclosure

Dr Karsh has been a speaker and a consultant for Augmenix. Drs Montoya and Gross worked with Augmenix to create a SpaceOAR application technique video. □

References

1. Dearnaley D, Syndikus I, Mossoo H et al. Conventional versus hypofractionated high-dose intensity-modulated radiotherapy for prostate cancer: 5-year outcomes of the randomised, non-inferiority, phase 3 CHHiP trial. *Lancet Oncol* 2016;17(8):1047-1060.
2. Aluwini S, Pos F, Schimmel E et al. Hypofractionated versus conventionally fractionated radiotherapy for patients with prostate cancer (HYPRO): late toxicity results from a randomised, non-inferiority, phase 3 trial. *Lancet Oncol* 2016;17(4):464-474.
3. Wortel RC, Incrocci L, Pos FJ et al. Late side effects after image guided intensity modulated radiation therapy compared to 3D-conformal radiation therapy for prostate cancer: results from 2 prospective cohorts. *Int J Radiat Oncol* 2016;95(2):680-689.
4. Catton CN, Lukka H, Gu CS et al. Randomized trial of a hypofractionated radiation regimen for the treatment of localized prostate cancer. *J Clin Oncol* 2017;35(17):1884-1890.
5. Cosgrove GR, Delashaw JB, Groenhuis JA et al. Safety and efficacy of a novel polyethylene glycol hydrogel sealant for watertight dural repair. *J Neurosurg* 2007;106(1):52-58.
6. Mettler L, Audebert A, Lehmann-Willenbrock E, Schive-Peterhansl K, Jacobs VR. A randomized, prospective, controlled, multicenter clinical trial of a sprayable, site-specific adhesion barrier system in patients undergoing myomectomy. *Fertil Steril* 2004;82(2):398-404.
7. Fargen KM, Hoh BL, Mocco J. A prospective randomized single-blind trial of patient comfort following vessel closure: extravascular synthetic sealant closure provides less pain than a self-tightening suture vascular compression device. *J Neurointerv Surg* 2011;3(3):219-223.
8. Masket S, Hovanesian JA, Levenson J et al. Hydrogel sealant versus sutures to prevent fluid egress after cataract surgery. *J Cataract Refract Surg* 2014;40(12):2057-2066.
9. Mariados N, Sylvester J, Shah D et al. Hydrogel spacer prospective multicenter randomized controlled pivotal trial: dosimetric and clinical effects of perirectal spacer application in men undergoing prostate image guided intensity modulated radiation therapy. *Int J Radiat Oncol Biol Phys* 2015;92(5):971-977.
10. Hamstra DA, Mariados N, Sylvester J et al. Continued benefit to rectal separation for prostate radiation therapy: final results of a phase III trial. *Int J Radiat Oncol Biol Phys* 2017;97(5):976-985.
11. Karsh LL, Gross ET, Pieczonka CM et al. Absorbable hydrogel spacer use in prostate radiotherapy: a comprehensive review of phase 3 Clinical trial published data. *Urology* 2017. (Epub ahead of print).
12. Roach M 3rd, Nam J, Gagliardi G, I. El Naqa I, Deasy JO, Marks LB. Radiation dose-volume effects and the penile bulb. *Int J Radiat Oncol Biol Phys* 2010;76(3 Suppl):S130-S134.
13. Hamstra DA, Mariados N, Sylvester J et al. Sexual quality of life following prostate intensity modulated radiotherapy (IMRT) with a rectal/prostate spacer: secondary analysis of a phase III trial. *Pract Radiat Oncol* 2018;8(1):e7-15.
14. Uhl M, van Triest B, Eble MJ, Weber DC, Herfarth K, De Weese, TL. Low rectal toxicity after dose escalated IMRT treatment of prostate cancer using an absorbable hydrogel for increasing and maintaining space between the rectum and prostate: results of a multi-institutional phase II trial. *Radiother Oncol* 2013;106(2): 215-219.
15. Pinkawa M, Klotz J, Djukic V et al. Learning curve in the application of a hydrogel spacer to protect the rectal wall during radiotherapy of localized prostate cancer. *Urology* 2013;82(4):963-968.
16. Fischer-Valuck BW, Chundury A, Gay H, Bosch W, Michalski J. Hydrogel spacer distribution within the perirectal space in patients undergoing radiotherapy for prostate cancer: Impact of spacer symmetry on rectal dose reduction and the clinical consequences of hydrogel infiltration into the rectal wall. *Pract Radiat Oncol* 2017;7(3):195-202.