

Physical examination of the epididymis made easy: a novel, reproducible and structured approach

Andrew Di Pierdomenico, MD, Darren Beiko, MD

Department of Urology, Queen's University, Kingston, Ontario, Canada

DI PIERDOMENICO A, BEIKO D. Physical examination of the epididymis made easy: a novel, reproducible and structured approach. *Can J Urol* 2014; 21(4):7396-7398.

The epididymis is the most common source of acute and chronic scrotal pain in the outpatient setting, yet there are no standardized methods for proper palpation of this organ. We describe a novel scrotal examination technique

that is reproducible and easy to learn. Our technique utilizes a maneuver we call testicular 'framing', and in our experience this maneuver almost invariably leads to proper diagnosis of epididymal pathology by facilitating successful palpation of the epididymal head, body and tail.

Key Words: epididymis, physical examination, palpation

Introduction

Acute scrotal pain poses a diagnostic challenge as its differential spans surgical emergencies to self-limited conditions requiring conservative management. Epididymitis is the most common etiology for this complaint in outpatients, and is overall the fifth most common genitourinary (GU) diagnosis in men aged 18-50.^{1,2} The physical exam plays an important role in establishing the diagnosis but is dependent on the operator's skill and interpretation of their findings.

We have observed that medical students and residents often struggle with reproducibly isolating the epididymis during the scrotal exam. One reason may be that most have not learned a standardized technique for doing so. Those who employ a strategy of 'just palpating' may benefit from learning a simple systematic approach. Here we demonstrate our technique for reliably isolating the epididymis during the scrotal exam.

Accepted for publication April 2014

Address correspondence to Dr. Darren Beiko, Department of Urology, Kingston General Hospital, 76 Stuart Street, Kingston, ON K7L 2V7 Canada

Method and technique

We begin the scrotal exam with the patient lying in the supine position. We use two drapes, the first is placed to cover the pelvis and the penis and the second is placed to cover the distal extremities from the level of the mid-thigh downwards. The result is adequate exposure of the scrotum with concealment of those areas not of interest to our exam, Figure 1.

We perform the exam while standing to the right of the patient. We arrange our hands such that each thumb and middle finger is apposed to its counterpart on the opposite hand. This maneuver creates a rectangular shaped 'frame' in the same plane as the patient, Figure 2.

We begin palpation by descending our hands towards the table directly onto the scrotum. The descent is made while keeping the 'frame' in the same plane as the patient and letting it fall directly onto the scrotum.

During palpation of the right epididymis (as shown in the Figures), the long border of the 'frame' comprised of the middle fingers should line up on the midline raphe of the scrotum and the long border of the 'frame' comprised of the thumbs should line up with the lateral border of the scrotum. For palpation of the

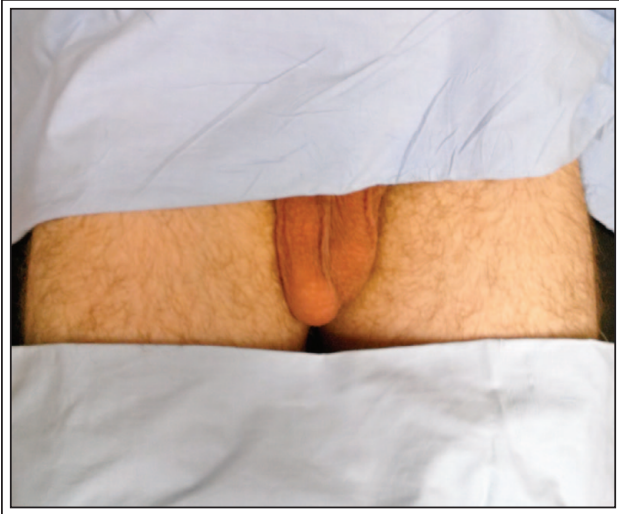

Figure 1. Male patient lying supine and draped prior to the scrotal exam.

left epididymis, the thumbs line up with the median raphe and the middle fingers line up with the lateral border of the scrotum.

With our hands on the scrotum we attempt to center the testicle within the 'frame' before descending the hands further towards the table. Once the testicle is through the 'frame', we flex our middle fingers in attempt to trap the epididymis against the point of apposition formed by our thumbs. The end result is an isolated epididymis trapped between the thumbs and middle fingers, Figure 3. Sliding the apposed thumbs and middle fingers from top to bottom along the course

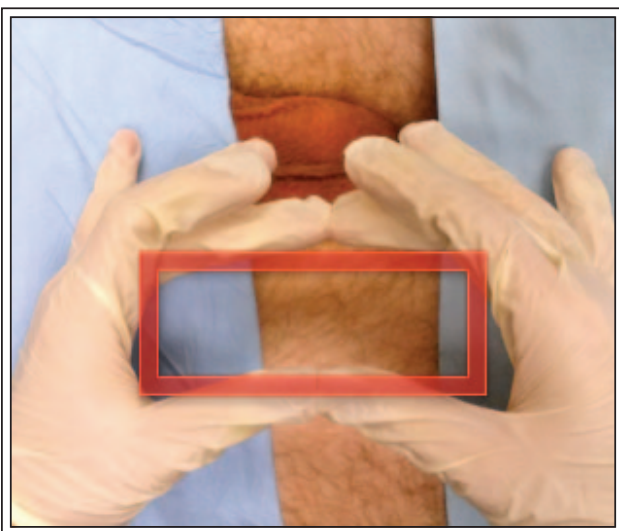


Figure 2. Rectangular 'frame' formed by the hands prior to scrotal palpation.

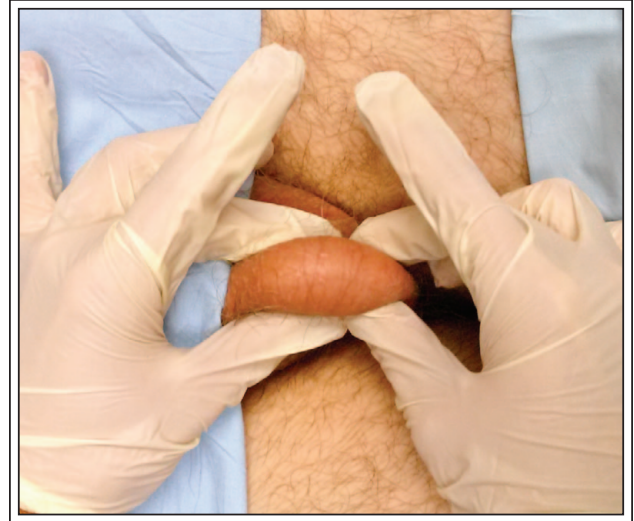

Figure 3. Final hand position demonstrating the epididymis fixed between the middle fingers and thumbs for easy palpation.

of the epididymis allows systematic examination of the epididymal head, body and tail. Additionally, this maneuver results in a testicle that protrudes upwards and through the 'frame' for easy digital palpation.

Discussion

We describe and demonstrate a technique for palpating the epididymis that is used at our institution. The strengths of the technique are its ease of use and reproducibility. In our experience urology trainees and medical students can learn to reliably define the head, body, and tail of the epididymis while performing the maneuver independently.

There are limitations to our testicular 'framing' maneuver for examining the epididymis. This technique may not be reliably performed in patients with large and/or tense hydroceles, other large scrotal masses or epididymal anteversion. A large and/or tense hydrocele results in the inability to reliably palpate the testis and epididymis. For a large scrotal mass, the physical size of the lesion in question may render testicular 'framing' impossible. Anteversion of the epididymis occurs in up to 7% of males.³ When this condition is present, our technique is of limited value because the epididymis develops and lies anterior to the testis. Importantly, one additional limitation of our technique is in the setting of acute scrotal pain, where significant pain, tenderness and swelling could certainly limit the ability to successfully perform this examination technique.

Unless a varicocele is present, we prefer to palpate the epididymis with the patient in the supine position. This facilitates appropriate draping and allows for this segment to be smoothly incorporated into a more general physical exam. Our technique of ‘framing’ the testicle and landmarking over the midline raphe has the benefit of delineating the structure of the entire testicle and allowing the examiner to be confident they are palpating over the epididymis. From this position it is easy to evaluate the testicle, spermatic cord, and remainder of the scrotum for pathology.

Our intention is for this maneuver to augment the male GU exam at a juncture that trainees often struggle to perform reliably. One explanation for this may be that popular learning resources only vaguely describe a technique for palpating the epididymis. For example, Bates’ Guide to Physical Examination and History-Taking recommends that the patient be standing or supine while the examiner palpates the epididymis with the “thumb and first two fingers”. An accompanying photograph then depicts an examiner using one hand to move the standing patient’s penis to the side and the other to palpate.⁴ Unfortunately there is no further description and from the photograph provided it is difficult to delineate the scrotal anatomy and the site of correct palpation. The urology text Campbell-Walsh Urology advises that the epididymis “should be palpable as a ridge posterior to each testis,” but does not provide either instructions for doing so or include a photograph for reference.⁵ For the experienced clinician these descriptions may suffice, but those unfamiliar with the anatomy may benefit from our structured approach.

A second explanation is that urology trainees struggle with the male GU exam because of insufficient opportunities to practice in medical school.⁶ In one study, 42% of female students and 29% of male students reported not performing a testicular exam in clerkship.⁷ At many academic institutions, including ours, not all medical students are required to rotate through the urology service.⁸ One of the top sources of student anxiety toward learning the male GU exam is “fear of causing harm or pain to the patient”.⁹ A clinical skills curriculum that uses standardized patient instructors or mannequin-based simulation to teach the male GU exam may improve medical student comfort with it.^{9,10} We expect that students who employ our approach for palpating the epididymis will be more confident in their skills and less fearful of causing undue discomfort to their patients.

Conclusions

We present a novel technique for palpation of the epididymis. Our structured approach is expected to allow urology trainees to reproducibly and confidently perform an important component of the scrotal exam. □

References

1. Trojian TH, Lishnak TS, Heiman D. Epididymitis and orchitis: an overview. *Am Fam Physician* 2009;79(7):583-587.
2. Collins MM, Stafford RS, O’Leary MP, Barry MJ. How common is prostatitis? A national survey of physician visits. *J Urol* 1998; 159(4):750-754.
3. LeBlond RF, Brown DD, DeGowin RL. DeGowin’s Diagnostic Examination, 9th Edition. 2009; Chapter 12. The Male Genitalia and Reproductive System.
4. Bickley, LS. Bates’ guide to physical examination and history taking – 11th ed. Copyright Wolters Kluwer Health, Lippincott Williams & Wilkins 2013; p. 528-531.
5. Gerber GS, Brendler CB. Campbell-Walsh Urology 10th ed. Chapter 3 – Evaluation of the Urologic Patient. Copyright Saunders, Elsevier Inc 2012; p. 82-83.
6. Hawkins R, Gross R, Beuttel S, Holmboe E, Gilva-McConvey G, Haley H. Use of standardized patients for teaching and evaluating the genitourinary examination skills of internal medicine residents. *Teaching and Learning Medicine: An International Journal* 1998;10(2):65-68.
7. Taylor JS, Dube CE, Pipas CF, Fuller BK, Lavallee LK, Rosen R. Teaching the testicular exam: A model curriculum from ‘A’ to ‘Zack’. *Fam Med* 2004;36(3):209-213.
8. Kaplan AG, Kolla SB, Gamboa AJ et al. Preliminary evaluation of a genitourinary skills training curriculum for medical students. *J Urol* 2009;182(2):668-673.
9. Pugh CM, Iantelli KB, Rooney D, Salud L. Use of mannequin-based simulation to decrease student anxiety prior to interacting with male teaching associates. *Teaching and Learning Medicine: An International Journal* 2012;24(2):122-127.
10. Robins LS, Alexander GL, Dicken LL, Belville WD, Zweifler AJ. The effect of standardized patient instructor experience on students’ anxiety and confidence levels performing the male genitoretal examination. *Teaching and learning medicine: An international journal* 1997;9(4):264-269.