

Robot assisted radical prostatectomy: how I do it. Part I: patient preparation and positioning

Roger F. Valdivieso, MD, Pierre-Alain Hueber, MD, Kevin C. Zorn, MD

University of Montreal Hospital Center (CHUM)-Hopital St. Luc, Montreal, Quebec, Canada

VALDIVIESO RF, HUEBER P-A, ZORN KC. Robot assisted radical prostatectomy: how I do it. Part I: patient preparation and positioning. *Can J Urol* 2013;20(5):6957-6961.

Radical prostatectomy remains the standard treatment for long term cure of clinically localized prostate cancer, offering excellent oncologic outcomes, with cancer-specific survival approaching 95% at 15 years after surgery. The introduction of the “da Vinci Robotic Surgical System” (Intuitive Surgical, Sunnyvale, CA, USA) has been another important step toward a minimally invasive approach to radical prostatectomy. Technologic peculiarities, such as three-dimensional vision, wristed instrumentation with seven degrees of

freedom of motion, lack of tremor, a 10x-magnification and a comfortable seated position for the surgeon has added value to the surgeon and patient. In this first part of a two article series, we describe preoperative patient preparation and positioning protocols for robot assisted radical prostatectomy (RARP) that are currently used in our institution (University of Montreal Hospital Center (CHUM) – Hopital St-Luc). We use the four-arm da Vinci Si Surgical System. Our experience with RARP is now over 250 cases with the senior surgeon having performed over 1200 RARPs and we have continually refined our technique to improve patient outcomes.

Key Words: surgical techniques, robot assisted radical prostatectomy, prostate cancer

Introduction

Radical prostatectomy remains the standard treatment for long term cure of clinically localized prostate cancer, offering excellent oncologic outcomes, with cancer-specific survival approaching 95% at 15 years after surgery.¹

Retropubic radical prostatectomy (RRP), laparoscopic radical prostatectomy (LRP) and robot assisted radical prostatectomy (RARP) are safe options for treatment of

patients with localized prostate cancer as they present similar overall complication rates.² RRP has long been the most common surgical technique used to treat clinically localized prostate cancer. More recently, since 2004-2005, RARP has been gaining increasing acceptance among patients and urologists, and it has become the dominant technique in the United States and many centers worldwide despite the lack of evidence demonstrating its superiority over the other modalities.² To this date there is no multicenter-randomized trial comparing RARP with the gold standard RRP or LRP to support the benefits of RARP. Short of high quality evidence, most of the comparative analyses are derived from single cohort and meta-analysis of large volume single center prospective studies. In this context, RARP has been associated with decreased operative blood loss

Accepted for publication August 2013

Address correspondence to Dr. Kevin C. Zorn, University of Montreal Health Center (CHUM), 235, boul. René-Levesque Est, suite 301, Montreal, QC H2X 1N8 Canada

and decreased risk of transfusion when compared with RRP.³ It has also been described that, with experienced robotic surgeons, RARP yields lower positive surgical margins (PSM) rates and higher continence and potency rates. Nevertheless, since there are no randomized trials and long term follow up studies comparing the three approaches, definitive conclusions cannot be drawn. However, such trial carries so many practical limitations including patient preference and surgeon variable expertise that it might likely never be undertaken. Despite this, RARP has become the leading option for treating patients with clinically localized prostate cancer in the United States, and has progressively gained acceptance in Europe and many centers worldwide.² Additionally, surgeon experience and institutional volume of procedures strongly predicts better outcomes. In particular the rates for both PSM and biochemical recurrence have been reported to decrease significantly with increasing experience.⁴

Although RARP is feasible using either a transperitoneal or extraperitoneal approach, most surgeons favor the transperitoneal approach. This preference is attributed to the greater working space and familiar landmarks of the pelvis and its contents associated with this access. Although some studies have shown that an extraperitoneal approach can yield shorter mean operative time, shorter time to full diet, shorter hospital stays and earlier return to continence, most studies have found little or no difference between the two procedures.⁵ Nevertheless, the use of the extraperitoneal approach may be favored in patients with morbid obesity or patients who had previous extensive abdominal surgery.⁶ In these particular cases, the peritoneum acts as a natural barrier, minimizing the potential for bowel injury and preventing the bowels from falling into the operative field and obscuring the surgeon's view. Another potential advantage of this approach is to confine any urine leak that may occur from the vesicourethral anastomosis within the extraperitoneal space. On the other hand, the main limitation with the extraperitoneal approach remains the reduced working space as compared with the relatively larger working space of the peritoneal cavity gained with transperitoneal access. Because of this, extended pelvic lymphadenectomy may be more challenging with this approach. Lastly, a higher CO₂ absorption has been reported with extraperitoneal versus transperitoneal insufflation, requiring a higher minute volume to compensate for hypercarbia and associated acidosis.⁷

Overall, whether to use one approach or the other is largely a matter of surgeon and institution preference and experience and there is no consistently demonstrated advantage for either approach.

Patient selection

Patients with localized prostate cancer are selected for RARP with the same indication as ORP or LRP and according to the American Urological Association (AUA) and Canadian guidelines.⁸ There is no absolute counter-indication to RARP. However obesity, previous abdominal surgery, larger prostate size, and previous radiation can be significantly more challenging. Hence, only experienced high volume surgeons should operate on these patients

Although there is no medical standard for an optimal time span between biopsy diagnosis and surgery, an interval of ≥ 4 -6 weeks is advised. However it has been shown that the time interval is not associated with perioperative or postoperative results.⁹

Preoperative preparations

A few weeks prior to surgery, a standard, thorough medical clearance including complete history and physical examination for any cardiopulmonary comorbidities and previous abdominal surgery is performed in outpatient's clinic before the date of surgery. At this time, the main surgeon obtains informed consent. During this meeting the advantages and the multiple risks are explained. We routinely provide our patients with the AUA update summary of all possible complications that have been reported with contemporary radical prostatectomy. In short, decreased sexual function, urinary incontinence, incisional hernias, adjacent organ injury, conversion to open surgery and the risks involved with general anesthesia. The procedure is also explained to the patient and the experience of the main surgeon is highlighted. Details of postoperative penile rehabilitation and pelvic floor rehabilitation are provided prior to surgery to allow the patient to optimize postoperative function. Patients are advised to begin Kegel exercises preoperatively and to continue the pelvic floor rehabilitation program for at least 1 year postoperatively to maximize the continence recovery rates. Patients are also invited to watch informational videos created by the surgical team that are available on the Internet (<http://www.youtube.com/user/drkevinzorn>) for further information about the surgery. We have also offered our patients to see the 2-week postoperative diaries of the last 250 patients, which is available on Facebook (<https://www.facebook.com/pages/Robotic-Urology-Dr-Kevin-Zorn-Canada-Prostate-Center/111671516833>). Finally, they are advised to communicate any questions and/or concerns through e-mail with the main surgeon.

Patients are advised to stop taking all anticoagulants 1 week before surgery. However, some emerging evidence suggests that allowing continued low dose nonsteroidal anti-inflammatory drugs or aspirin is not associated with the occurrence of bleeding events and could be beneficial in preventing serious adverse cardiac thrombotic events.

Patients are typically admitted the night prior to the day of surgery and are asked to start a liquid diet beginning at noon that day followed by strict NPO at midnight with no additional specific bowel preparation.

Surgical team

The surgical team consists of the main surgeon, a surgical assistant (usually a trained urology resident), a circulating nurse, a scrub nurse, the anesthetist and respiratory therapist. Each member is knowledgeable in robotic assisted surgery and has been trained and credentialed as per our institutional robotic committee.

Patient positioning

Once the patient is under general anesthesia his position is secured with the Allen's Hug-u-Vac steep trend positioner. This device is filled with soft microbeads that enables it to inflate and deflate evenly, when suction is applied. After positioning the patient, the device is deflated with a hand-held pump and its pliable shape conforms to the contours of the patient's body preventing sliding. Arms are tucked in with foam rolls in the palms of the hands and 'kidney' shaped shoulder braces are carefully placed over the acromioclavicular joint to avoid brachial plexus injury. Sequential compression stockings are put in place over the thromboembolic (TED) stockings. The patient's legs are placed in padded boot stirrups in the low lithotomy position, see Figure 1. An orogastric tube may be placed to decompress the gastrointestinal tract. A 20Fr Foley catheter is typically installed to drain the bladder and to ensure that it is completely decompressed and outside of the field of port placement.

Only after this preparation has been completed, is the patient put in Trendelenburg position at an inclination of 20-25 degrees to facilitate exposure of the pelvic content. Studies have shown that patients undergoing this procedure in a steep Trendelenburg position for 3h-4h do not present significant cerebrovascular, respiratory or hemodynamic problems. However, caution is advised for longer operative time, in particular for patients with glaucoma, as prolonged trendelenburg position can increase intra-ocular pressure.

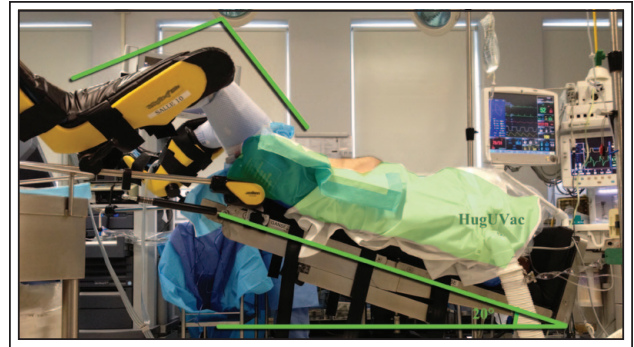

Figure 1. Patient positioning for robot assisted radical prostatectomy. The patient is placed on steep (20 degrees) Trendelenburg position and then secured with the Allen's Hug-u-Vac steep trend positioner (Allen Medical Systems, Acton, MA, USA (http://www.allenmedical.com/uploads/files/pdf/D-770599_A1_Allen_Hug-u-Vac_Steep_Trend_Slicksheet_NP.pdf))

Note the low lithotomy positioning of the legs including a slight bend of the hip and knee to prevent traction nerve injury. Furthermore, sequential compressive device are placed over anti-embolic stockings to reduce the incidence of thromboembolic events.

A recent study evaluated for the first time the risk factors and incidence of positioning injuries associated with RARP.¹⁰ They found that these injuries occur in 6.6% of cases and includes radial and medial nerve palsy, hip adduction or flexion weakness and other neuropraxias. The major factors that put patients at risk of developing these injuries are length of the procedure, especially lasting more than 5 hours, and multiple patient comorbidities. Therefore, patients at higher risk are to be advised of these possible positional complications.

Ultimately, the abdominal, genital and perineal areas are scrubbed with Solu-IV (Chlorexidine based disinfectant clear solution) followed by sterile draping.

Anesthesia considerations

Because of the possibility of severe hemorrhage, which in laparoscopic approach can be difficult to control, discontinuation of anticoagulants and antiplatelet agents 1 week prior to surgery must be ensured. Even though bleeding is rarely significant enough to require a transfusion, typing and screening of blood is performed for every patient. Cross-matching for units of blood is not a routine practice for a standard case.

Since RARP is a laparoscopic procedure with an open urinary tract (clean contaminated), a single

course of antibiotic is given at induction in prophylaxis. In patients with no penicillin allergy, a first generation cephalosporin such as Ancef 1g is given intravenously.

Finally upon induction, 5000 units of Heparin are given subcutaneously for thromboprophylaxis and two 650 mg suppositories of acetaminophen are administered intrarectally to diminish postoperative pain and opiates consumption.

Any lines, monitors and patient protective devices are placed and secured before draping. Special care with regards to the endotracheal tube must be taken to avoid it from becoming kinked or pulled out. Once the robot is over the patient with its arms attached to the ports, the patient cannot be moved. If cardiopulmonary resuscitative measures must be initiated the robot is first detached.

The use of pneumoperitoneum with the steep Trendelenburg position is known to cause both respiratory and hemodynamic effects. Among the respiratory effects there is a decreased functional residual capacity, decreased pulmonary compliance and increased peak airway pressures. This positioning also increases the workload of the heart and elevates the mean arterial pressure, central venous pressure and systemic vascular resistance.

Patients for RARP require general endotracheal anesthesia with mechanically controlled ventilations. Any of the anesthetic drugs may be used dependent on the patient's cardiovascular status and presence of other comorbidities. In order to achieve optimal pneumoperitoneum complete muscle relaxation is essential.

Other than the standard monitoring used in any general endotracheal anesthetic case, additional monitoring and/or intravenous fluid lines is dependent upon the patient's medical condition and the experience of the operating team.

Intraoperative intravenous fluids are kept to a minimum (< 2000 mL) because excessive urine output might obscure the operative field during vesicourethral anastomosis. Fluid restriction might also minimize the facial, pharyngeal, and laryngeal edema that may occur from prolonged use of steep Trendelenburg position.

Port placement

A Standard 6-port placement configuration is drawn on the patient's abdomen prior to skin incisions. Pneumoperitoneum is established using a Veress needle through a 12 mm sub-umbilical incision. The use of this technique prevents injury to intra-abdominal organs. After confirmation of the correct passage and location of the needle we start the insufflation at 1-2 L/min

for a total of 3-5 L. An intraperitoneal pressure of 20 mmHg is then achieved and we proceed to confirm that the abdomen is uniformly distended and that the patient is able to tolerate pneumoperitoneum. Then, the Veress needle is retrieved and a 12 mm trocar is placed for insertion of the stereo endoscope. After pneumoperitoneum is established and the patient is stable, primary inspection of the intraperitoneal cavity is performed to ensure that no injuries to the bowel or adjacent organs have occurred and to verify the presence of adhesions. Secondary trocars are then placed using laparoscopic guidance to avoid injuring main arteries of the abdominal wall, see Figure 2. One particular challenge to port placement and the procedure in general is the obese patient. In such patients the anatomical landmarks are difficult to identify and the distance from the surgical site is difficult to estimate. Moreover, there is the potential for restricted instrument range of motion and reach due to a thicker abdominal wall, as well as decreased intrapelvic working space due to increased omental fat. For these reasons exposure and closure of the specimen extraction site are often challenging in obese men. Variation in equipment (bariatric instruments and longer trocars) is often required. Consequently, ports are placed more cephalad from the pubic symphysis and deeper into the body with lateral deflection of the robot arms.

The left anterior superior iliac spine (ASIS) is identified and a point which is approximately 2-3

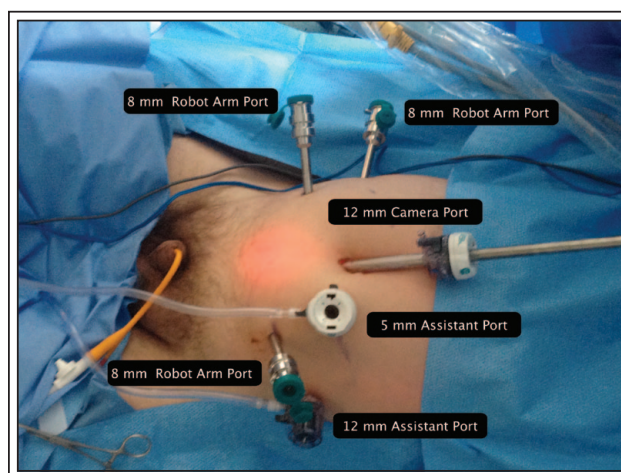


Figure 2. Standard six-port placement for robot assisted radical prostatectomy. Two 12 mm, three 8 mm and one 5 mm trocar are placed in the standard way providing sufficient distance between the camera and working ports to prevent internal or external collision of instruments.

fingerbreadths superior and 1-2 finger breadths medial to this landmark is marked out for the insertion of the 12 mm assistant port. The 8 mm robotic arm port is then placed approximately 10 cm away from the midline camera port slightly below the umbilicus and lateral to the edge of the rectus muscle. For the second assistant suction port (5 mm), an imaginary line is drawn connecting the left sided 8 mm robotic port and the midline camera port and, at the midline of this line the port is inserted under visualization. On the right side of the patient, an 8 mm fourth robotic arm port is placed using the same landmarks as the 12 mm left-sided lateral assistant port. Finally, another 8 mm right sided robotic working port in a position which is an exact mirror image to the 8 mm left-sided robotic port.

Overall, three 8 mm metallic robotic trocars are used by the working robotic arms of the surgeon while the assistant provides retraction, suction, and irrigation and passes clips and sutures via the 12 mm and 5 mm trocars placed along the patient's right side. Finally, a total of 20 mL of Marcaine is injected in all trocar incisions for postoperative anesthesia. A smoke evacuator is also used during the procedure to optimize vision.

Robot docking

The patient cart is maneuvered into position to align the patient cart tower, camera arm and target anatomy. One member of the surgical team maneuvers the patient cart while another one guides the driver. Room references are used to avoid any confusion during docking. The cart is pushed into position and the brakes at the base of the cart are hand tightened.

The camera arm is the first one connected to the patient and the instrument arms follow. Once all the robotic arms are connected, the surgical team checks each arm for proper working distance and makes sure the arms are not compressing the patient. The fourth arm is docked on the right side of the patient while the bed-side assistant is situated on the patient's left side.

Part II will be published in the upcoming *Can J Urol* December 2013 issue. □

3. Ficarra V, Novara G, Ahlering TE et al. Retropubic, laparoscopic, and robot-assisted radical prostatectomy: a systematic review and cumulative analysis of comparative studies. *Eur Urol* 2009;55(5): 1037-1063.
4. Tsivian M, Zilberman DE, Ferrandino MN, Madden JF, Mouraviev V, Albala DM. Apical surgical margins status in robot-assisted laparoscopic radical prostatectomy does not depend on disease characteristics. *J Endourol* 2012;26(4):361-365.
5. Brown JA, Rodin D, Lee B, Dahl M. Transperitoneal versus extraperitoneal approach to laparoscopic radical prostatectomy: an assessment of 156 cases. *Urology* 2005;65(2):320-324.
6. Atug, F, Thomas R. Transperitoneal versus extraperitoneal robotic-assisted radical prostatectomy: which one? *Minerva Urol Nefrol* 2007;59(2):143-147.
7. Meiningner D, Byhahn C, Wolfram M, Mierdl S, Kessier P, Wetphal K. Prolonged intraperitoneal versus extraperitoneal insufflation of carbon dioxide in patients undergoing totally endoscopic robot-assisted radical prostatectomy. *Surg Endosc* 2004;18(5):829-833.
8. Thompson I, Thrasher JB, Aus G et al. Guideline for the management of clinically localized prostate cancer: 2007 update. *J Urol* 2007;177(6):2106-2131.
9. Kim IS, Na W, Nam JS et al. Interval from prostate biopsy to robot-assisted laparoscopic radical prostatectomy (RALP): effects on surgical difficulties. *Korean J Urol* 2011;52(10):664-668.
10. Mills JT, Burris MB, Warburton DJ, Conaway MR, Schenkman NS, Krupski TL. Positioning injuries associated with robotic assisted urological surgery. *J Urol* 2013;190(2):580-584.

References

1. Liss M, Osann K, Ornstein D. Positive surgical margins during robotic radical prostatectomy: a contemporary analysis of risk factors. *BJU Int* 2008;102(5):603-608.
2. Montorsi F, Wilson TG, Rosen RC et al. Best practices in robot-assisted radical prostatectomy: recommendations of the Pasadena Consensus Panel. *Eur Urol* 2012;62(3):368-381.