

Ureteral diverticulum: a review of the current literature

Louise C. McLoughlin, Niall F. Davis, Catherine Dowling, Molly P. Eng, Richard E. Power

Department of Urology and Transplant Surgery, Beaumont Hospital, Dublin, Ireland

McLOUGHLIN LC, DAVIS NF, DOWLING C, ENG MP, POWER RE. Ureteral diverticulum: a review of the current literature. *Can J Urol* 2013;20(5):6893-6896.

Introduction: Ureteral diverticulum is a rare urological condition with only 45 cases described in the literature. These previously reported cases vary in their presentation, diagnosis and management and there is no consensus in the literature on the best diagnostic tool available. We describe our experience on diagnosing and managing this condition in two patients and provide a descriptive review of the current literature on ureteral diverticulum.

Materials and methods: A Medline search was performed to identify all reported cases of ureteral diverticulum. Key words used were: ureteral diverticulum; abortive bifid ureter; congenital diverticulum; acquired diverticulum. We also reviewed the records of two patients who presented consecutively to our institution with a ureteral diverticulum. The clinical and radiological characteristics of this entity were then evaluated.

Results: Forty-one manuscripts were identified, encompassing single case reports and case series, the largest of which contained seven patients. Two additional cases were diagnosed in our institution; a true congenital diverticulum and an abortive bifid ureter which is synonymous with a true ureteral diverticulum. Both were uncomplicated cases and were managed conservatively. Retrograde pyelography was used for definitive diagnosis of this lesion.

Conclusion: Ureteral diverticulum may present as an incidental finding or with a secondary complication. Conservative management is advocated in the literature for non-complicated cases. Retrograde pyelography is our diagnostic tool of choice.

Key Words: retrograde pyelography, review, ureteral diverticulum, abortive bifid ureter, congenital diverticulum, acquired diverticulum

Epidemiology

Ureteral diverticula are rare urological entities with 45 cases described in the literature. The most frequently reported diverticulum is an abortive bifid ureter, ending blindly at one of the proximal ends¹⁻⁶ and least commonly, acquired diverticulum that arise secondary to the presence of ureteral calculi⁷ or as a complication of surgery.^{8,9} Two further cases of ureteral diverticulum were diagnosed in our institution.

Accepted for publication July 2013

Address correspondence to Mr. Richard E. Power, Department of Urology and Transplant Surgery, Beaumont Hospital, Beaumont, Dublin 9 Ireland

Classification

Ureteral diverticula are sub-classified into three categories: 1) abortive ureteral duplications (a blind-ending bifid ureter: the same embryogenesis as diverticula, arising from disordered ureteric budding, different from diverticulum in its appearance); 2) true congenital diverticulum containing all tissue layers of the normal ureter; 3) acquired diverticulum representing mucosal herniation.^{10,11}

The pathogenesis of an acquired ureteral diverticulum is a distally obstructed ureter. This may be due to a distal calculus causing an increase in pressure that results in a proximal ureteral diverticulum similar to the development of a vesical diverticulum in patients with benign prostatic hypertrophy. These

patients present in a symptomatic fashion with flank pain and fever. In addition, strictures, and ureteral valves may produce a similar picture and present symptomatically.¹⁰ Mucosal herniation may also result from a congenital weakness in the ureter that permits ballooning when the intra-ureteral pressure is increased.¹² Ureteric calculi may also occur in conjunction with true congenital diverticulum, there are four such cases reported in the literature.^{1,13-15}

The first series of diverticula reported in 1975 concluded that although the potential for the development of these lesions may arise from congenital mal-developments, the natural history also depends on an abnormal hypo-dynamic state that may be acquired in childhood or adult life.¹⁶

Diverticula can present with painless hematuria^{2,13,16-19} or be entirely asymptomatic and present as an incidental finding on imaging.^{10,16,17} The diverticulum may then become associated with obstructive uropathy when a ureteral calculus sits in the pouch and causes ureteral stenosis proximal to the stone filled pouch and consequent hydronephrosis.^{17,18,20} Pyelonephritis can then occur, causing sepsis necessitating the insertion of a ureteric stent to relieve the obstruction, as reported by Mori et al. They concluded that a diverticulum, unlike a ureterocele, will not cause obstruction, but a stone in the pouch will.¹³ In our institution, one patient had an abortive bifid ureter while the other had a true congenital diverticulum. Visible, painless hematuria was the presenting complaint in both cases and one was associated with a ureteral calculus which passed after cystoscopic insertion of a ureteric stent.

Ureteral diverticula have been described in association with complex pelvic and abdominal abnormalities^{19,21,22} and have been reported in the pediatric population in association with other congenital anomalies.^{11,23}

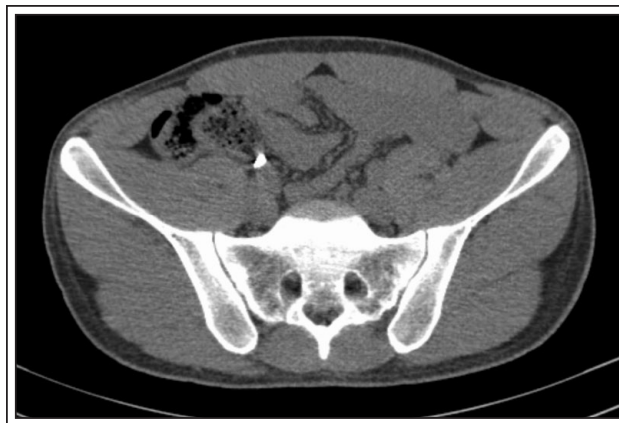

Figure 1. CTU showing 8 mm calcification in distal ureter.

Diagnosis and treatment options

Radiological imaging is the mainstay of diagnosis among reported cases. Ultrasonography was initially advocated by Wan et al²⁴ and Herndon then went on to describe the first antenatally detected ureteral diverticulum with the use of antenatal ultrasound.¹⁰ CT is generally used in symptomatic cases where a ureteral stone was subsequently found to be sitting in the pouch causing obstruction.¹³ However, the sensitivity of CTU in picking up diverticula associated with ureteric calculi may be debatable. In our experience, CT did not pick up the diverticulum in the patient with a ureteric calculus, Figure 1 but it was diagnosed in the other calculus-free case, Figure 2. The use of non contrast magnetic resonance tomography, CT and repeated target ultrasonography using color mapping and 3D reconstructions has also been reported.¹⁷ We used retrograde pyelography to confirm the diagnosis in both our patients,

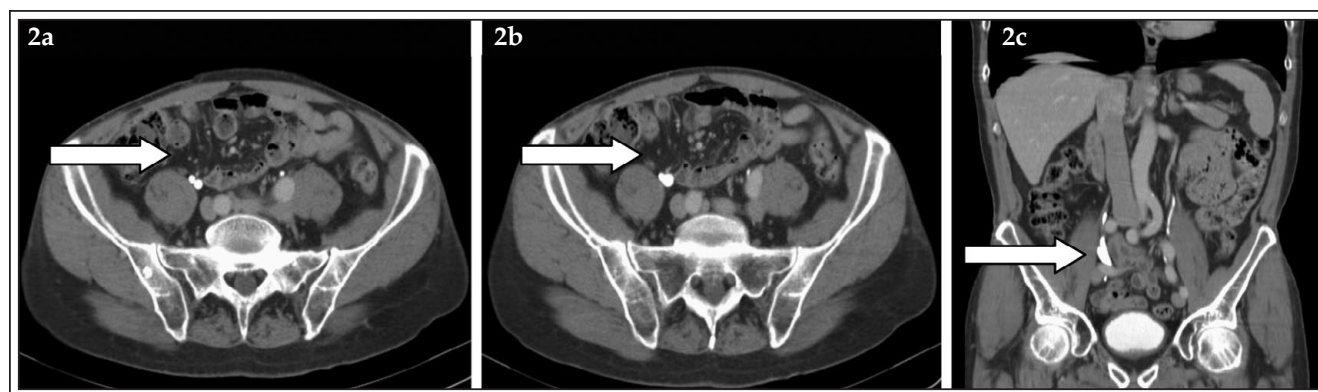


Figure 2. CTU showing a ureteral diverticulum filled with contrast in the axial (2a and 2b) and coronal (2c) planes.

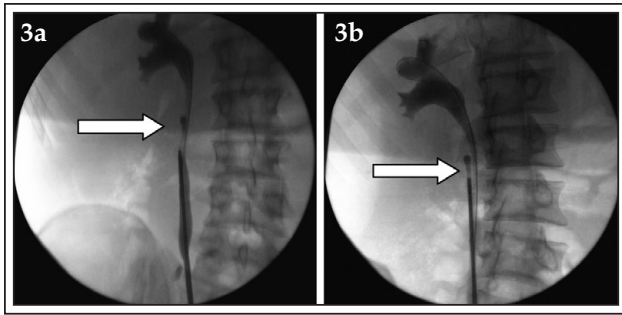


Figure 3a and 3b. Retrograde pyelogram showing a ureteral diverticulum; abortive bifid ureter type.

Figure 3 and Figure 4. This has not been reported previously in the literature.

In the majority of reported cases, and in our experience, ureteral diverticula do not require treatment.^{16,17} If the diverticulum becomes associated with obstruction, treatment is then initiated. We also elected for conservative management in our patients and at most recent follow up, both patients were well and asymptomatic.

There are early reports of nephrectomy¹⁴ and partial ureterectomy of the affected portion of ureter for management of diverticula associated with obstruction.²⁰ Later, reconstructive surgery was also shown to have a role in alleviating obstruction secondary to diverticula.²⁵

Diverticulectomy with segmental resection of the ureteral diverticulum with an end-to-end anastomosis is currently advocated in cases where the urine refluxes and stagnates, causing urinary tract infection.^{5,23} This may be done after interval placement of a ureteric stent to allow the sepsis to subside.¹³

More recently, successful laparoscopic resection of acquired ureteral diverticula has been described by Li et al in 2006.²⁶

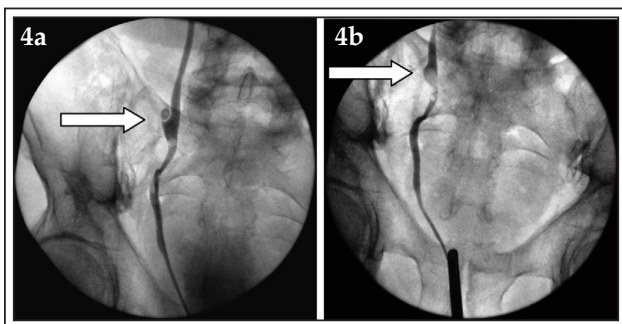


Figure 4a and 4b. Retrograde pyelogram showing a true congenital diverticulum.

Prognosis

The general prognosis of untreated, uncomplicated ureteral diverticula is excellent^{16,17,24} however there have been reported cases of some adverse events. The occurrence of TCC in a lower ureteral diverticulum has been described²⁷ and perforation of a diverticulum can also occur.¹ Fibroepithelial polyps have also become associated with these lesions but it is hypothesized that ureteral diverticula and fibroepithelial polyps are part of a spectrum of the same developmental anomaly and do not have any bearing on prognosis.²⁸

Douglas et al reported on patients who developed hydroureteronephrosis and were subsequently treated with surgical excision. At 4 year follow up their renal function remained normal with no deterioration on excretory urography.¹⁸

Conclusion

Ureteral diverticulum is a rare entity that has been classified in the literature into congenital or acquired lesions. They are generally asymptomatic unless they become associated with ureteral stones causing obstruction. We advocate the use of retrograde pyelography for diagnosis of these lesions as the sensitivity of CTU has not been proven. Conservative management should be employed in asymptomatic cases with no evidence of hydroureteronephrosis. □

References

1. Cappellani A, Di Vita M, Zanghi A, Lo Menzo E, Conti P. Perforation of a ureteral diverticulum: a case report and review of the literature. *Annali italiani di chirurgia* 2003;74(3):349-352; discussion 52-53.
2. Sanroma Ortueta I, Fernandez Goenaga JM, Lopez Garcia JA, Garmendia Larrea JC, Arocena Lanz F. [Ureteral diverticula. Apropos of 2 cases]. *Archivos españoles de urologia* 1989;42(5):466-468.
3. Biliotti G, Cappucci M, Corsi C, Mazzamurro G, Proietti G, Russo V. [A case of bifid ureter, one with a blind end: ureteral diverticulum?]. *Minerva urologica* 1983;35(2):161-163.
4. Sacco M. [On some unusual dysplasias of the uteter: blind branch of a bifid ureter and ureteral diverticulum. Presentation of 2 cases]. *Nuntius radiologicus* 1967;33(11):1383-1395.
5. Cendron J, Saied H, Trottot P. [Bifid ureter ending blindly at one of its upper ends. 4 cases (author's transl)]. *Journal d'urologie et de nephrologie* 1975;81(10-11):775-783.
6. Tanaka S, Sakamoto W, Ezaki K et al. [Blind-ending bifid ureter: a case report]. *Hinyokika kyo Acta urologica Japonica* 1985;31(3): 483-487.

Ureteral diverticulum: a review of the current literature

7. Schaad P. [Ureteral diverticulum: diagnosis due to a concomitant lithiasis]. *Bulletin et memoires de la Societe des chirurgiens de Paris* 1969;59(1):47-51.
8. Kuzuhara K, Sugimoto H, Takahashi I et al. [Acquired ureteral diverticulum after renal transplantation (a case report of acquired ureteral diverticula) (author's transl)]. *Nihon Hinyokika Gakkai zasshi* 1978;69(12):1660-1666.
9. Aragona F, Bassi P, Passerini Glazel G, Pagano F. Acquired intravesical ureteral diverticulum: an unusual late complication of ureteroneocystostomy. *J Urol* 1989;141(6):1420-1421.
10. Herndon CD, McKenna PH. Antenatally detected proximal ureteral diverticulum. *Urology* 2000;55(5):774.
11. Johnin K, Kadowaki T, Kushima M et al. Congenital ureteral diverticulum coexistent with hydronephrosis caused by vascular compression involving the uterine artery and umbilical ligament: report of a case. *J Pediatr Surg* 2000;35(9):1350-1352.
12. Rank WB, Mellinger GT, Spiro E. Ureteral diverticula: etiologic considerations. *J Urol* 1960;83:566-569.
13. Mori C, Yamada D, Homma Y. A case of calculus in the true ureteral diverticulum. *Int J Urol* 2011;18(2):180-181.
14. Culp OS. Ureteral diverticulum classification of the literature and report of an authentic case. *J Urol* 1947;58(5):309-321.
15. Pratt JG, Gahagan HG, Fischman JL. Diverticulum of the ureter: a review of the literature and a report of two additional cases. *J Urol* 1947;58(5):322-326.
16. Barrett DM, Malek RS. Ureteral diverticulum. *J Urol* 1975;114(1):33-35.
17. Builov VM, Sencha AN. [Ureteral diverticulum]. *Urologiia (Moscow, Russia:1999)* 2010;(2):63-65.
18. Douglas LL, Pott GA. Case report: congenital ureteral diverticulum and solitary kidney. *J Urol* 1979;122(3):401-402.
19. Anraku T, Mizusawa T, Obara K, Sato H, Ajioka Y, Takahashi K. [A case of true ureteral diverticulum on functional solitary kidney]. *Nihon Hinyokika Gakkai zasshi* 2012;103(3):569-572.
20. Yoshida S, Nakagomi K, Goto S. [A case of true ureteral diverticulum]. *Nihon Hinyokika Gakkai zasshi* 2005;96(1):25-28.
21. Bowie CW, Garvey FK, Boyce WH, Pautler EE. Supernumerary urinary bladder and ureter, spiral deformity of the ureter, ureteral diverticulum, hypoplasia of the kidney and bicornate uterus: a case report. *J Urol* 1954;71(3):293-298.
22. Benchekroun A, Belahnech Z, Faik M et al. [Didelphic uterus, blind hemi-vagina, renal agenesis with right, homolateral ureteral diverticulum with ectopic opening into the vulva and female hypospadias]. *Progres en urologie* 1991;1(4):600-605.
23. Cope RM, Snow BW. Massive cystic ureteral diverticula in infancy. *J Urol* 1991;146(2 (Pt 2)):575-577.
24. Wan YL, Hsieh ML, Hsueh C, Shum HC, Kea CL. Sonographic diagnosis of a ureteral diverticulum. *J Ultrasound Med* 1996;15(6):483-485.
25. Ono Y, Watanabe J, Yamada S et al. [Reconstructive surgery of obstructive disease of the upper urinary tract]. *Nihon Hinyokika Gakkai zasshi* 1989;80(9):1321-1326.
26. Li JR, Chiu KY, Lin HM, Cheng CL, Yang CR, Hung SW. Laparoscopic excision of a ureteral diverticulum. *Int J Urol* 2006;13(7):995-996.
27. Harrison GS. Transitional cell carcinoma in a congenital ureteral diverticulum. *J Urol* 1983;129(6):1231-1232.
28. Franco I, Choudhury M, Eshghi M, Bhalodi A, Addonizio JC. Fibroepithelial polyp associated with congenital ureteral diverticulum: report of 2 cases. *J Urol* 1988;140(3):598-600.