
The management of prostatic obstruction with urethral stents

Charles C. Peyton, MD, Gopal H. Badlani, MD

Department of Urology, Wake Forest Baptist Medical Center, Winston-Salem, North Carolina, USA

PEYTON CC, BADLANI GH. The management of prostatic obstruction with urethral stents. *Can J Urol* 2015;22(Suppl 1):75-81.

Introduction: Elderly men with multiple comorbidities may be unfit to undergo surgical management of benign prostatic obstruction (BPO). Permanent and temporary prostatic stents have been developed as an alternative to chronic indwelling catheters in men unfit for surgery.

Materials and methods: Herein we review the past and present literature on the role and effectiveness of prostatic stents in the treatment of BPO.

Results: Permanent prostatic stents have largely been abandoned in North America due to unfavorable outcomes and improved technologies to allow for treatment of

BPO. Currently, the temporary Spanner stent is the only available stent on the market, but its effectiveness has mostly been documented for temporary relief of tissue edema following minimal invasive ablative treatments for BPO.

Conclusions: The advent of well-tolerated surgical treatments for BPO (KTP laser vaporization, bipolar TURP, urethral lift devices) has diminished the need for permanent prostatic stents. The temporary Spanner stent is an alternative to urethral catheter, but requires adequate detrusor function and can cause irritative symptoms.

Key Words: temporary prostatic stents, permanent prostatic stents, prostatic obstruction, urethral stent, elderly

Introduction

As the aging male population continues to increase urologists will be challenged to manage benign prostatic obstruction (BPO) in elderly men with comorbidities that may escalate their risk of surgical complication. Approximately 30% of patients with lower urinary tract symptoms (LUTS) will fail to achieve satisfactory improvement with lifestyle modifications and medications alone.¹ Although older studies suggest mortality and morbidity rates of 0.2% and 18%, respectively, transurethral resection of the prostate (TURP) still remains the gold standard for treatment.² More current evaluations of TURP suggest a mortality rate of 0.1% and short term morbidity rate of 11.1%, most common being failure

to void.³ Technologic advancements have significantly improved the ability of the surgeon to provide a safe and effective TURP.⁴ However, certain elderly patients with comorbidities may be unfit for surgery, unwilling or unable to perform intermittent catheterization and better suited for a chronic indwelling catheter or alternative treatment.

The concept of an indwelling, intraprostatic stent was first described in 1980 by Fabian et al and the evolution of this idea has gone through several permutations.⁵ The ideal goals of such a device is to promote prostatic urethral patency while maintaining continence, it should be easy to insert without a general anesthetic, provide an alternative to indwelling foley catheter and improve quality of life at a reduced cost compared to surgery. Both permanent and temporary prostatic stents have been developed and tested throughout the years. Broadly, the goal of permanent stents was to allow epithelialization of the stent to prevent urinary crystallization while maintaining

Address correspondence to Dr. Gopal H. Badlani, Department of Urology, Wake Forest Baptist Medical Center, Medical Center Blvd., Winston-Salem, NC 27157-1094 USA

patency of the prostatic lumen. Temporary stents were designed to prevent epithelial ingrowth thereby making removal easy within a few weeks or up to 6 months. The concept of biodegradable stents that do not require manual removal has also been investigated.

Unfavorable results with the use of permanent urethral stents and the development of new technologies to address BPO, such as laser vaporization and bipolar TURP, has largely contributed to recent disinterest in prostatic urethral stents.⁶ Currently, there is only one FDA approved temporary urethral stent in North America, Spanner Temporary Prostatic Stent (SRS Medical, N. Billerica, MA, USA), and permanent urethral stents for prostatic obstruction have been removed from the market. Much of the development of other temporary stents has taken place in Europe. As such, options remain limited for patients with bladder outlet obstruction secondary to BPO who are unfit for a procedure requiring general anesthesia. Catheterization (intermittent, indwelling and suprapubic) affects quality of life, may cause family distress and carries a risk of recurrent urinary tract infections. Herein we will review the research, development and shortcomings of prostatic stents for the treatment of BPO.

Permanent prostatic stents

The concept of a permanent prostatic stent was developed following the success of endovascular stenting first performed as early as 1969. Fabian and colleagues first developed a “partial catheter” intraprostatic stent in 1980.⁵ The principle concept of permanent stents was to allow for epithelialization and embedding of the metal stent into the wall of the urethra, similar to endovascular stents.⁷ Milroy and colleagues reported on the initial investigation of the first permanent implantable stent for bulbourethral strictures in 1988.⁸ Subsequently the Urolume Wallstent (American Medical Systems, Minnetonka, Minnesota, USA) was developed and used in elderly men with significant comorbidities deemed unfit for surgery.^{9,10} The Urolume stents were composed with an expandable, wide mesh stainless-steel weave, Figure 1. The initial clinical trial of the Urolume Wallstent included 126 men with LUTS due to BPO and follow up over 2 years.¹⁰ They reported improvement in total symptom score, increased peak urinary flow rate and decreased in post void residual (PVR) urine, and epithelialization of the stents by 12 months. Thirteen percent of the devices required removal.¹⁰ Masood and colleagues performed a 12 year follow up analysis of 62 patients with Urolume implantation.¹¹ Unfortunately, 47% of patients required stent explanation most often

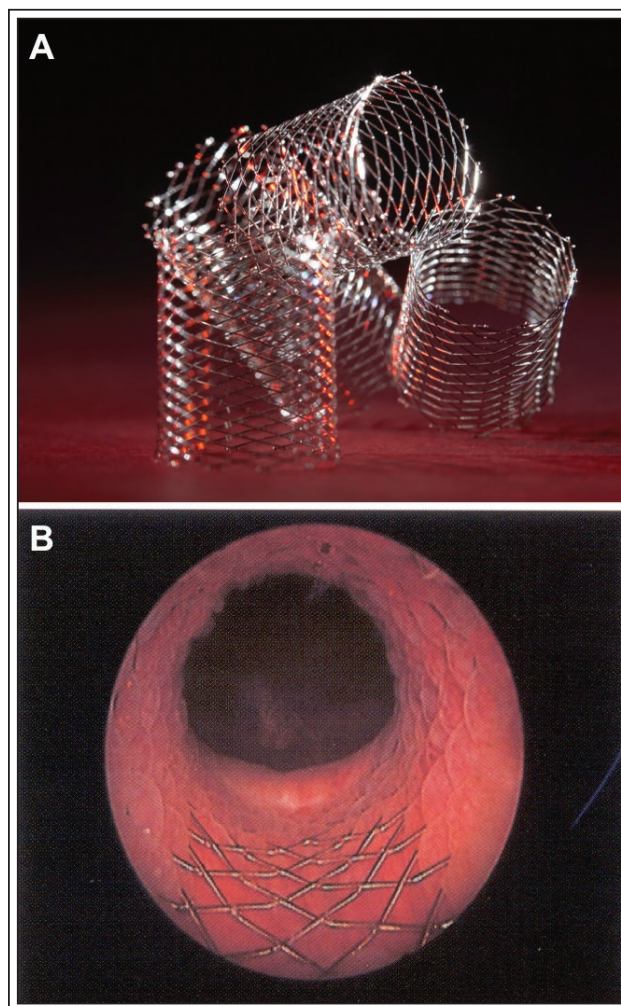


Figure 1. Urolume wallstents (American Medical Systems, Minnetonka, MN, USA) pre-deployment (A) and in situ at the prostatic urethra (B).

within the first 2 years and commonly due to stent migration or malpositioning, Figure 2a.¹² Late stent removal was due to progressive outlet obstruction due to encrustation and symptom progression, Figure 2b. Thirty-one men (34%) died during the study due to unrelated causes and only 11 men (18%) made it to 12 years with the device in place. Mean improvement in IPSS score was approximately only 3 points and there was no difference in peak urinary flow rate between 5 and 12 years. Furthermore, only 8 of the remaining 11 stents were completely epithelialized.

Several other international studies had similar results suggestive that the device was effective in improving ability to spontaneously void after insertion and improvement in symptoms.^{13,14} However, Armitage et al published the most comprehensive

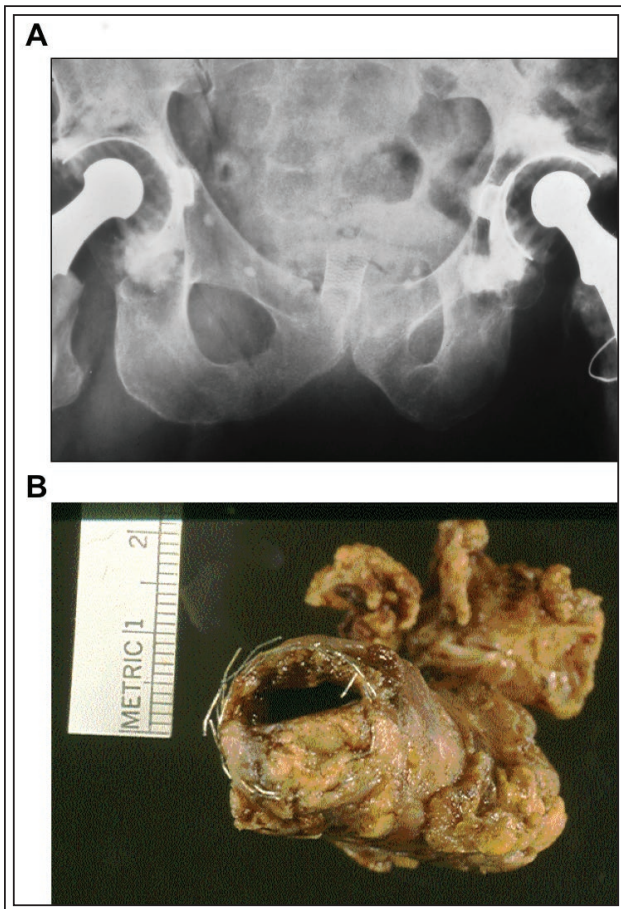


Figure 2. A) Proximal stent migration. B) Urethrectomy specimen demonstrating Urolume stent encrustation and hyperplastic growth.

systematic review of the Urolume in 2007 including 990 patients treated with Urolume.⁶ They concluded that the device improved spontaneous voiding and symptoms in 80% of men; however, 1 in 6 men required explanation of the Urolume within 12 months of insertion due to worsening irritative symptoms, progressive obstruction, encrustation and migration, Figure 2. The key shortcoming was the cylindrical design of the stent versus the rhomboid shape of the prostatic urethra, the anterior surface being shorter than the posterior. Thus accurate placement at the bladder neck resulted in uncovered posterior surface or exposed stent anteriorly. Another issue was the fully expanded lumen of the Urolume was 42 french, and prostatic urethra at its widest could have a larger lumen. Therefore, the stent apposed the anterior surface but floated from the posterior surface leading to stent exposure and subsequent complications. This was clearly different from its use in the bulbar

urethra that demonstrated long term favorable results when used for 2.5 cm strictures.¹⁵ The Prostakath (Engineers and Doctors A/S, Copenhagen, Denmark) was another epithelizing stent developed in the 1990s that also failed to demonstrate acceptable results with approximately 50% of patients requiring removal within the first year.^{16,17}

The limitations of the Urolume lead to development of the next generation of permanent prostatic stents composed of a titanium nickel alloy that has memory and flexibility based on temperature control (Memokath, Engineers and Doctors A/S, Hornback, Denmark). When flushed with warm water (> 45°C) the distal portion of the stent expanded to maintain position in the apical prostatic urethra. Cooling the same section with 10°C or below fluid made the spiral pliable and allowed for removal.¹⁸ The largest evaluation of these stents was performed by Perry and colleagues in 2002.¹⁹ Over 8 years, 211 men considered to be high risk surgical candidates underwent Memokath stent placement for obstruction. The average age was 80 years old and over 50% were considered frail. The authors report a mean IPSS improvement of 12.1 points after stent insertion. However, similar to previous prostatic stents, over 20% of the stents required removal and stent migration occurred in 29% of patients. The authors highlight that 38% of patients died with the stents in place and used Kaplan-Meier survival analysis to suggest that the stents may fail, but patients are more likely to die first. They conclude that the Memokath offers a valuable addition to the management of outlet obstruction in frail, elderly men. Lee et al performed a similar but much smaller study and had similar conclusions.²⁰

Given the experience with the Memokath stents, a new nitinol urethral stent was developed in the United States aimed at preventing migration using an hourglass shape, bell shape and increased diameter (Horizon, Endocare, Irving, CA, USA). Unfortunately, similar results were reported. Stent migration was common, only 7% of patients kept the stent in place after 21 months and there was no significant changes in peak urinary flow rate, PVR or IPSS.²¹ Another permutation of the Memokath stent was the Memotherm stent (Angiomed, Germany) developed as a thermosensitive prostatic stent. The original results were encouraging for the treatment of PBO,²² and one of the more recent evaluations of prostatic stents suggested favorable results at 5 years with the Memotherm.²³ However, these studies were very small sample size (25-55 patients) and stent migration, worsening symptoms and encrustation continued to be an issue in a number of patients.

Review of the current literature regarding permanent prostatic stents is more historical than current. The urologic community has largely abandoned the idea of permanent urethral stents secondary to unfavorable outcomes with prior stent experience and the development of improved technologies to allow for prostatic vaporization or resection on less healthy patients.¹² However, for patients who are unable to tolerate any general anesthesia and an indwelling foley catheter or SP tube is unacceptable to the patient, temporary prostatic stents may be of some benefit.

Temporary prostatic stents

The concept of temporary prostatic stent placement was popularized following the development of office based minimally invasive thermotherapy (MIT) for BPO such as transurethral microwave thermotherapy (TUMT) and needle ablation (TUNA) of the prostate. These procedures cause soft tissue coagulation necrosis and post-procedural edema with temporary worsening of the prostatic obstruction, requiring catheter placement. An attractive use for urethral stents then became temporarily relieving the obstruction without leaving an indwelling catheter. The idea quickly evolved into the development of biodegradable stents that facilitate emptying in the post-procedural period and did not require removal.

Initial reports of biodegradable polyglycolic acid (PGA) stents suggested they may be helpful in relieving temporary obstruction following MIT.^{24,25} Two major disadvantages to these stents were the variable rates of degradation and the relatively small lumen leading to many reports of urinary retention and associated clot obstruction. Petas et al performed an initial randomized control trials of biodegradable PGA stents following interstitial laser coagulation of the prostate versus no stent.^{24,25} The results of both studies suggested that stented patients had improvement in peak urinary flow rates and symptoms scores by 1 and 6 months post procedure. However, two major drawbacks was the high rate of urinary tract infections (41% in one study) and diminished force of stream perceived within 3 weeks of insertion secondary to active stent degradation.

Further study by Devonec et al evaluated two types of temporary stents.²⁶ Following high energy TUMT, 42 patients received a silicone transurethral removable prostatic bridge and 16 patients received a self-reinforced PGA biodegradable spiral stent. Voiding symptoms were assessed at 1 week and at 1, 3, 6 and 12 months after TUMT. The prostatic bridge was quite similar in shape to a foley catheter and

lodges proximal to the external urethral sphincter. It was removed 1 month following TUMT. The PGA stent had a degradation time of 3-4 weeks. At 1 week there was no improvement in symptom score, flow rate or voided volume. Patients who received the silicone stent demonstrated significant improvement in symptoms and peak flow rate at 1 month. However, patients who received the spiral stent did not show improvement until 3 months for symptoms and 1-3 months for flow rates. Overall, improvements in symptoms score, peak flow rate and voided volume were observed in both groups after 6 months, but this is likely more reflective of the TUMT instead of the use of a stent. Considering that the stents were either removed or degraded by 1 month, this study did not provided convincing evidence to support the use of temporary silicone or biodegradable PGA stent placement following TUMT.

The use of biodegradable stent for diagnostic purposes has also been reported.^{27,28} For patients with both BPO and detrusor overactivity (DO) there is a risk of urge incontinence following TURP. Knutson et al evaluated the use of a biodegradable PGA stent to simulate post-TURP results and assess the risk of urge incontinence.²⁸ Thirty-seven patients were stented and the device degraded within 3-4 weeks. At 2 months 25 patients denied any leakage and were recommended to undergo TURP. However, 23 patients did report worsening irritative symptoms with the stent in place and five patients were treated for a urinary tract infection. At the time of the study 18 of the 25 non-leaking patients had undergone TURP and reported significantly improved IPSS without differences in peak flow or PVR. This study did not provide evidence for the effectiveness of biodegradable stents to treat BPO and further highlighted the irritative effects of prostatic stents. However, it did provide an alternative use for prostatic stents as a pre surgical prognostic tool.

Commercially available stents

Currently, the only commercially available temporary prostatic stent is the Spanner stent (SRS Medical, North Billerica, MA, USA). The Spanner was designed to overcome the shortcomings of biodegradable prostatic stents. The stent design appears quite similar to a foley catheter, but the external urethral sphincter is not stented open and allows for coaptation. As seen in Figure 3, the proximal balloon rests at the bladder neck to prevent distal migration, the plastic lumen spans the length of the prostate (it must be sized appropriately), and a distal plastic anchor rests beyond the urethral sphincter preventing proximal migration. The device

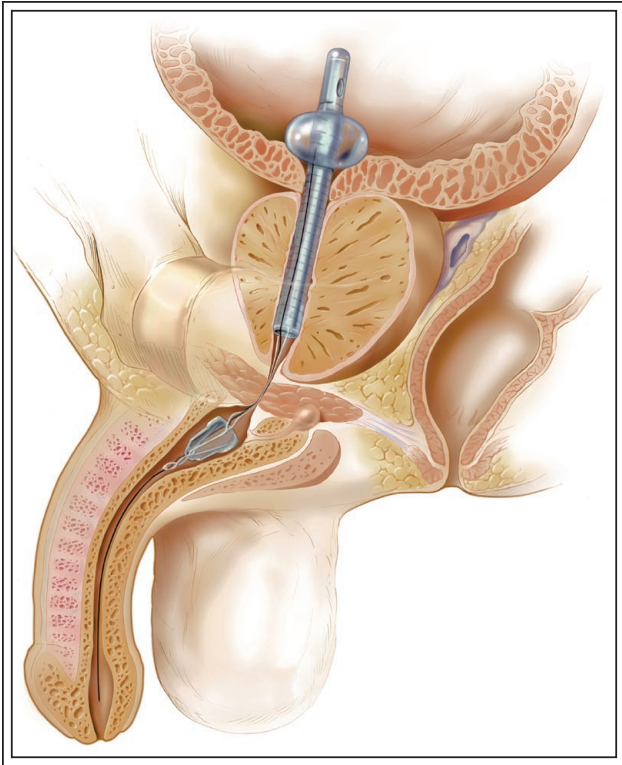


Figure 3. Spanner stent, reproduced with permission from SRS Medical, N. Billerica, MA, USA.

is attached to a retrieval suture within the penile urethra that deflates the balloon and allows for device removal when pulled. The FDA labeling approves use of the device for up to 30 days following minimally invasive benign prostatic hyperplasia (BPH) treatment and after post-treatment catheterization. However, other uses include temporary usage of 90 days for bladder outlet obstruction, differential diagnosis of detrusor hypocontractility versus outlet obstruction, alternative for foley catheter placement, obstruction relief following treatment of localized prostate cancer (brachytherapy, cryotherapy) and postoperative urinary retention.²⁹⁻³²

Corica et al described the initial evaluation of the Spanner in 30 patients with prostatic obstruction.³² The stent remained in situ for a mean of 57 days. They did not report any migration of the stent, stent encrustation or difficulty removing the stent. They reported significantly improved peak flow rates, PVR and IPSS after stent placement. Further study by Shore and colleagues randomized 186 patients to Spanner insertion for 30 days or less or standard care (temporary foley catheter placement) following TUMT.³³ The authors report significant improvements in PVR, peak flow rate, average flow and voided

volume while the Spanner stent was in place. After removal of the stent at 5 weeks post procedure no differences were noted. Perhaps more importantly, the Spanner group demonstrated an 8-point decrease in IPSS symptoms scores by week one post procedure and significant improvement in IPSS quality of life scores during stent placement and after removal. The margin of IPSS symptom improvement was most notable with the stent in place, but by 8 weeks post procedure the standard of care and stent placement groups IPSS improvements were similar (10-12 point improvement). A total of 5-device malfunctions were reported (one device migration) and none were associated with an adverse event or required treatment. The overall results suggest that the Spanner stent is safe and effective in improving emptying problems in the post procedural healing time following minimally invasive therapy for BPH. However, the most notable limitation of this study was the lack of long term follow up. Uroflowmetry, PVR and IPSS data was only collected up to 1 week following stent removal, therefore the durability of results is certainly in question. Additional investigation revealed quite similar results.³⁴ The Spanner stent provided improvement in measurable voiding symptoms without increase in irritative symptoms following temporary placement after TUMT. Once again, detrusor function and long term durability of the results was not evaluated.

Reported adverse events associated with the Spanner stent are not dissimilar from previous stents, including symptomatic urinary tract infection, stent migration, stent expulsion, encrustation, hematuria, clot retention and urinary retention. However, the risk of adverse event is not significantly different when compared to patients treated with only a foley catheter.³³ The only reported difference was the rate of perineal pain was significantly more common with the spanner stent versus foley catheter (26% versus 12.8%, respectively).³³

Grimsley and colleagues evaluated the usefulness of the Spanner stent for prostatic outlet obstruction in 42 elderly men over one year who were unfit for TURP.³⁰ Unfortunately, less than 40% of the patients in this review actually benefited from temporary stenting. Intolerable symptoms (nocturia, dysuria, frequency and urgency), immediate or delayed urinary retention, or preference for convenience of indwelling catheter resulted in premature removal of the stent in 63% of patients. Collectively the available studies suggest that the Spanner stent may be beneficial for temporary improvement in post procedural symptoms following minimally invasive ablative therapy of

the prostate. However, the device does not appear efficacious in managing prostatic BOO in patients unfit for surgery.³¹ It should be noted that temporary stents rely on intact volitional voiding and detrusor contractility coordinated with pelvic floor relaxation. Patients with detrusor function abnormalities are poor candidates for temporary stents. Corujo and colleagues demonstrated that patients with detrusor hypocontractility will not benefit from temporary prostatic stents.³⁵ Hardly any investigational studies of temporary stents evaluated detrusor function.

Conclusion

The advent of minimally invasive destructive therapies (KTP laser and bipolar TURP) and non-destructive (urethral lift) have decreased the need for permanent prostatic stents. Currently, there are no FDA approved permanent prostatic stents on the North American market. However, there still remains a need for a temporary device to replace a foley catheter for temporary obstructive relief and/or post MIT obstruction. Optimal temporary prostatic stent design should provide an alternative for foley catheter, maintain continence, not require general anesthetic for insertion, limit associated irritative symptoms/pain and improve quality of life. The only approved temporary stent on the market achieves several of these requirements, but still may cause irritative symptoms. The literature lacks assessment of bladder function for many of the clinical studies for prostatic stents. It is important to remember that prostatic stenting may not help men with lack of bladder contractility, unlike passive drainage with a foley catheter. Further development is needed to design an ideal prostatic stent for the management of BPO.

Disclosure

Dr. Charles C. Peyton and Dr. Gopal H. Badlani have no disclosures. □

References

1. Roehrborn CG. Male lower urinary tract symptoms (LUTS) and benign prostatic hyperplasia (BPH). *Med Clin North Am* 2011; 95(1):87-100.
2. Mebust WK, Holtgrewe HL, Cockett AT, Peters PC. Transurethral prostatectomy: immediate and postoperative complications. A cooperative study of 13 participating institutions evaluating 3,885 patients. *J Urol* 1989;141(2):243-247.

3. Reich O, Gratzke C, Bachmann A et al. Morbidity, mortality and early outcome of transurethral resection of the prostate: a prospective multicenter evaluation of 10,654 patients. *J Urol* 2008;180(1):246-249.
4. Rassweiler J, Teber D, Kuntz R, Hofmann R. Complications of transurethral resection of the prostate (TURP)—incidence, management, and prevention. *Eur Urol* 2006;50(5):969-979; discussion 980.
5. Fabian KM. [The intra-prostatic “partial catheter” (urological spiral) (author’s transl)]. *Urologe A* 1980;19(4):236-238.
6. Armitage JN, Cathcart PJ, Rashidian A, De Nigris E, Emberton M, van der Meulen JH. Epithelializing stent for benign prostatic hyperplasia: a systematic review of the literature. *J Urol* 2007; 177(5):1619-1624.
7. Corujo M, Badlani GH. Epithelialization of permanent stents. *J Endourol* 1997;11(6):477-480.
8. Milroy EJ, Chapple CR, Cooper JE et al. A new treatment for urethral strictures. *Lancet* 1988;1(8600):1424-1427.
9. Milroy E, Chapple CR. The UroLume stent in the management of benign prostatic hyperplasia. *J Urol* 1993;150(5 Pt 2):1630-1635.
10. Oesterling JE, Kaplan SA, Epstein HB, Defalco AJ, Reddy PK, Chancellor MB. The North American experience with the UroLume endoprosthesis as a treatment for benign prostatic hyperplasia: long-term results. The North American UroLume Study Group. *Urology* 1994;44(3):353-362.
11. Masood S, Djaladat H, Kouriefs C, Keen M, Palmer JH. The 12-year outcome analysis of an endourethral wallstent for treating benign prostatic hyperplasia. *BJU Int* 2004;94(9):1271-1274.
12. Vanderbrink BA, Rastinehad AR, Badlani GH. Prostatic stents for the treatment of benign prostatic hyperplasia. *Curr Opin Urol* 2007;17(1):1-6.
13. Guazzoni G, Montorsi F, Coulange C et al. A modified prostatic UroLume Wallstent for healthy patients with symptomatic benign prostatic hyperplasia: a European Multicenter Study. *Urology* 1994;44(3):364-370.
14. Williams G, Coulange C, Milroy EJ, Sarramon JP, Rubben H. The urolume, a permanently implanted prostatic stent for patients at high risk for surgery. Results from 5 collaborative centres. *Br J Urol* 1993;72(3):335-340.
15. Badlani GH, Press SM, Defalco A, Oesterling JE, Smith AD. Urolume endourethral prosthesis for the treatment of urethral stricture disease: long-term results of the North American Multicenter UroLume Trial. *Urology* 1995;45(5):846-856.
16. Nordling J, Ovesen H, Poulsen AL. The intraprostatic spiral: clinical results in 150 consecutive patients. *J Urol* 1992;147(3):645-647.
17. Thomas PJ, Britton JP, Harrison NW. The Prostakath stent: four years’ experience. *Br J Urol* 1993;71(4):430-432.
18. Poulsen AL, Schou J, Ovesen H, Nordling J. Memokath: a second generation of intraprostatic spirals. *Br J Urol* 1993;72(3):331-334.
19. Perry MJ, Roodhouse AJ, Gidlow AB, Spicer TG, Ellis BW. Thermo-expandable intraprostatic stents in bladder outlet obstruction: an 8-year study. *BJU Int* 2002;90(3):216-223.
20. Lee G, Marathe S, Sabbagh S, Crisp J. Thermo-expandable intraprostatic stent in the treatment of acute urinary retention in elderly patients with significant co-morbidities. *Int Urol Nephrol* 2005;37(3):501-504.
21. van Dijk MM, Mochtar CA, Wijkstra H, Laguna MP, de la Rosette JJ. Hourglass-shaped nitinol prostatic stent in treatment of patients with lower urinary tract symptoms due to bladder outlet obstruction. *Urology* 2005;66(4):845-849.
22. Gottfried HW, Schlumers HP, Gschwend J, Brande E, Hautmann RE. Thermosensitive stent (Memotherm) for the treatment of benign prostatic hyperplasia. *Arch Esp Urol* 1994;47(9):933-943; discussion 943-936.
23. Bozkurt IH, Yalcinkaya F, Sertcelik MN, Zengin K, Ekici M, Yigitbasi O. A good alternative to indwelling catheter owing to benign prostate hyperplasia in elderly: Memotherm prostatic stent. *Urology* 2013;82(5):1004-1007.

24. Petas A, Isotalo T, Talja M, Tammela TL, Valimaa T, Tormala P. A randomised study to evaluate the efficacy of a biodegradable stent in the prevention of postoperative urinary retention after interstitial laser coagulation of the prostate. *Scand J Urol Nephrol* 2000;34(4):262-266.
25. Petas A, Talja M, Tammela TL, Taari K, Valimaa T, Tormala P. The biodegradable self-reinforced poly-DL-lactic acid spiral stent compared with a suprapubic catheter in the treatment of post-operative urinary retention after visual laser ablation of the prostate. *Br J Urol* 1997;80(3):439-443.
26. Devonec M, Dahlstrand C. Temporary urethral stenting after high-energy transurethral microwave thermotherapy of the prostate. *World J Urol* 1998;16(2):120-123.
27. Knutson T. Can prostate stents be used to predict the outcome of transurethral resection of the prostate in the difficult cases? *Curr Opin Urol* 2004;14(1):35-39.
28. Knutson T, Pettersson S, Dahlstrand C. The use of biodegradable PGA stents to judge the risk of post-TURP incontinence in patients with combined bladder outlet obstruction and overactive bladder. *Eur Urol* 2002;42(3):262-267.
29. Henderson A, Laing RW, Langley SE. A Spanner in the works: the use of a new temporary urethral stent to relieve bladder outflow obstruction after prostate brachytherapy. *Brachytherapy* 2002;1(4):211-218.
30. Grimsley SJ, Khan MH, Lennox E, Paterson PH. Experience with the spanner prostatic stent in patients unfit for surgery: an observational study. *J Endourol* 2007;21(9):1093-1096.
31. McKenzie P, Badlani G. Critical appraisal of the Spanner prostatic stent in the treatment of prostatic obstruction. *Med Devices* 2011;4:27-33.
32. Corica AP, Larson BT, Sagaz A, Corica AG, Larson TR. A novel temporary prostatic stent for the relief of prostatic urethral obstruction. *BJU Int* 2004;93(3):346-348.
33. Shore ND, Dineen MK, Saslawsky MJ, Lumerman JH, Corica AP. A temporary intraurethral prostatic stent relieves prostatic obstruction following transurethral microwave thermotherapy. *J Urol* 2007;177(3):1040-1046.
34. Dineen MK, Shore ND, Lumerman JH, Saslawsky MJ, Corica AP. Use of a temporary prostatic stent after transurethral microwave thermotherapy reduced voiding symptoms and bother without exacerbating irritative symptoms. *Urology* 2008;71(5):873-877.
35. Corujo M, Badlani GH, Regan JB, et al. A new temporary catheter (ContiCath) for the treatment of temporary, reversible, postoperative urinary retention. *Urology* 1999;53(6):1104-1107.