

---

# *Photoselective laser ablation of the prostate: a review of the current 2015 tissue ablation options*

Côme Tholomier, MD, Roger Valdivieso, MD, Pierre-Alain Hueber, MD, Kevin C. Zorn, MD

Section of Urology, Department of Surgery, Centre Hospitalier de l'Université de Montréal, Montréal, Quebec, Canada

---

THOLOMIER C, VALDIVIESO R, HUEBER P-A, ZORN KC. Photoselective laser ablation of the prostate: a review of the current 2015 tissue ablation options. *Can J Urol* 2015;22(Suppl 1):45-52.

**Introduction:** *Transurethral resection of the prostate (TURP) is still considered the gold standard to treat benign prostatic hyperplasia (BPH). However, photoselective vaporization of the prostate (PVP) has gained widespread acceptance as an alternative option requiring preoperative patient selection. Four laser systems are currently in use: holmium, thulium, diode and GreenLight.*

**Materials and methods:** *The goal of this article is to review the physics and the basics behind laser prostatectomies, as well as to present the most current literature concerning the results, advantages, disadvantages and international recommendations for each vaporization procedure.*

**Results:** *Holmium laser ablation of the prostate (HoLAP) and GreenLight photoselective vaporization of the prostate are an alternative to TURP for small to*

*medium-sized prostates, providing equivalent efficacy and safety. GreenLight is also safe and effective in large-sized prostates and especially beneficial in anti-coagulated individuals compared to TURP. Thulium vaporization of the prostate (ThuVAP) and diode vaporization both require additional randomized trials and long term studies before conclusion is made, despite promising initial results. Diode vaporization provides the best hemostasis overall, but at the cost of increased complication and re-treatment rate, and thus is not recommended except in severely anti-coagulated patients.*

**Conclusion:** *Laser vaporization is a safe and effective alternative to TURP in the treatment of benign prostatic hyperplasia (BPH) for carefully selected patients. However, further research is still needed to assess the durability of each technology.*

**Key Words:** BPH, BOO, laser, prostate, PVP, HoLAP, ThuLAP, photovaporization, ablation, LUTS, surgery, outcomes

---

## Introduction

Transurethral resection of the prostate (TURP) and open prostatectomy are considered to be the gold standard in the treatment of lower urinary tracts symptoms (LUTS) secondary to benign prostatic hyperplasia (BPH).<sup>1</sup> In an effort to improve functional outcomes and efficacy, to offer treatment to higher risk men (elder age, anticoagulation, larger prostate size) and to reduce morbidity, hospital stay and overall medical cost, alternative therapies have been developed. More specific, laser prostatectomy, originally used by the urology community for the treatment of urinary tract stones, was contemporarily

adapted for the treatment of symptomatic bladder outlet obstruction by Gilling et al.<sup>2</sup> Since the turn of the century, laser BPH surgery has gained significant adoption worldwide, particularly in the United States,<sup>3</sup> Canada<sup>4</sup> and Europe.<sup>5</sup> Given the changing face of BPH male presenting for surgical treatment coupled with healthcare economics, reimbursement and patient education, minimally invasive laser therapy has been welcomed as a promising modality. After numerous clinical trials and meta-analyses, laser vaporization technologies, notably 2100 nm Holmium and 532 nm Greenlight, are now recognized in clinical guidelines by the American Urological Association (2010) and the European Association of Urology (2012 and 2015) as effective alternatives to TURP for the treatment of BPH.<sup>1,6-8</sup> In particular, holmium laser enucleation of the prostate is recommended as first choice for the patient with a prostate volume superior to 80 cc. Similarly

---

Address correspondence to Dr. Kevin C. Zorn, University of Montreal Health Center (CHUM), 235, boul. René-Levesque Est, suite 301, Montreal, QC H2X 1N8 Canada

laser vaporization should be considered in patients receiving anticoagulant medication or with a high cardiovascular risk as intraoperative safety of 532 nm laser vaporization is superior to TURP.<sup>1</sup>

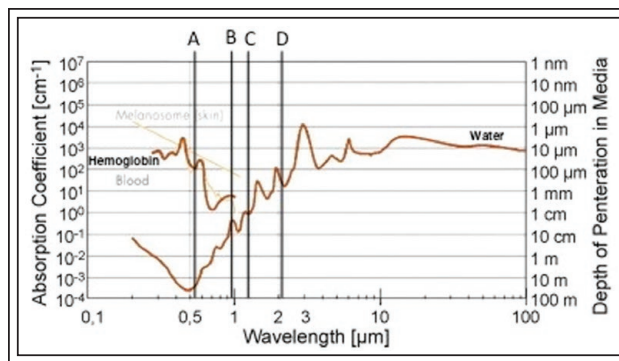
Among the numerous commercially available laser wavelengths, there are currently four laser systems approved and utilized by the urology community for photovaporization of the prostate to treat obstructive BPH. These include holmium, GreenLight, diode and thulium. All have their own characteristics and spectrum of application. These lasers can be used for the treatment of obstructive adenoma using three techniques: vaporization, resection and enucleation.

1. Vaporization or ablation: the adenoma is vaporized progressively and no tissue is retrieved as specimen.
2. Resection or vaporesction: involves cutting the adenoma into small pieces that needs to be retrieved.
3. Enucleation consists of an anatomic separation of the adenoma of the surgical capsule, followed by morcellation into the bladder. This approach was developed with the use of holmium laser but has been also performed using a 532 nm laser as GreenLEP (Greenlight Laser Enucleation of the Prostate), or a thulium laser as ThuLEP (Thulium Laser Enucleation of the Prostate).

A combination of these can also be used. All the techniques that aim to treat adenoma, causes reduction of prostate size and symptom relief of bladder outlet obstruction (BOO). This review will specifically focus on the photovaporization technique, complications and outcomes.

### Basics of laser vaporization

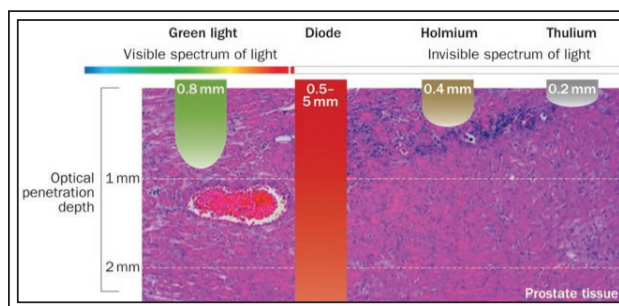
“Laser” originated as an acronym meaning “Light Amplification by Stimulation Emission of Radiation”. In other terms, laser is a coherent beam of light that is produced using electromagnetic radiation and a laser medium. Excitation of the active medium (such as a crystal, glass, gas or a dye) is achieved by the use of an excitation source (such as the photons from a flash lamp). Some of these photons will be absorbed by the medium and will then be spontaneously emitted leading to the creation of the laser (i.e. stimulation emission of radiation). The various lasers systems used differ in the active medium, the excitation source, as well as in its wavelength and in the mode of operation.<sup>9</sup> The laser can either be employed in a continuous-wave or in pulsed-wave mode. Vaporization then becomes possible by simple rapid heating of the tissue above the boiling point.<sup>10</sup> Both modes can thus be used to resect or ablate a prostatic adenoma, to vaporize or to coagulate.<sup>11</sup>



**Figure 1.** Absorption spectrum of hemoglobin and water depending on the wavelength of the laser. Chromophore absorption at point A: 532 nm (Greenlight), at point B: 940 nm-980 nm (Diode) lasers, at point C: 1318 nm-1470 nm (Diode lasers) and at point D: 2013 nm-2100 nm (Holmium and Thulium lasers).

Once the laser beam is produced, it needs to be delivered to the tissues using optical fibers. Different fibers are used; all with the interest to maximize energy and their lifespan by preventing their degradation and carbonization by the laser beam output.<sup>11,12</sup>

The final characteristic, and most important, is the light distribution and tissue absorption (laser-tissue interaction). The therapeutic and thermal effects vary depending on the laser properties (wavelength, power, mode) and the composition or content of chromophore of the targeted tissue. In the prostatic tissue, the two main potential targeted chromophores are hemoglobin and intracellular water. By modifying the wavelength of the lasers used, the target chromophore as well as the absorption coefficient and the depth of penetration will vary greatly. Figure 1



**Figure 2.** Optical penetration depth of the different laser systems. The tissue penetration primarily depends on laser wavelength and power output. Thulium-based lasers have the shallowest penetration depth, whereas diode lasers penetrate the deepest.

summarizes the absorption characteristics of the four lasers used to treat BPH. Figure 2 compares the optical penetration and subsequent thermal impact on tissue between the difference laser wavelengths. In summary, holmium or thulium laser systems, with a wavelength of approximately 2100 nm and 2000 nm, respectively, have a penetration depth of 0.4 mm and 0.2 mm respectively as they are preferentially absorbed by water. In contrast, GreenLight laser with a wavelength of 532 nm is selectively absorbed by hemoglobin and has a penetration depth of 0.8 mm. Diode lasers, depending on the wavelength (from 940 nm, 980 nm, 1318 nm to 1470 nm), will have a much deeper penetration up to 5 mm-7 mm.

The two basic mechanisms by which laser therapy ablate prostatic tissue are induced by thermal injury and are vaporization and coagulative necrosis.<sup>13</sup> When the optic energy from the laser beam is concentrated to the treated area, it is converted to thermal energy, which progressively heat the tissue. A temperature of 50°C to 100°C will produce tissue coagulative necrosis (i.e. tissue is heated high enough to denaturize proteins without reaching the boiling point). There is a potential delayed but clinically significant anatomical debulking of the prostatic urothelium that is used by some of the laser therapies such as diode, since it leads to a gradual improvement of symptoms over weeks

following the procedure. In contrast, vaporization takes place with temperature higher than 100°C (i.e. once the temperature is above the boiling point).<sup>14</sup> Below the vaporized area, a rim of coagulation necrosis is observed as temperature decreases away from the source, which prevents bleeding.

The main disadvantage of the photoselective vaporization technique is that no specimen is available for analysis after the procedure is completed. Therefore there is a potential risk of missing a prostate cancer diagnosis. This is why the urologist needs to rule out the latter before the procedure: digital rectal exam, PSA testing and prostate biopsy may be required.

### Laser photoselective vaporization: current choices


As of 2015, four different types of laser can be used for prostate vaporization treatment: holmium, thulium diode, and the 532 nm-laser system, Figure 3. As previously mentioned, all such lasers can be used not only to vaporize the prostatic tissue but also to resect (i.e. vaporesection) or to enucleate (i.e. vapoenucleation) the prostatic adenoma. While these have been published in the literature, only the vaporization/ablation technique will be covered in this chapter.

### Holmium: holmium laser ablation of the prostate (HoLAP)

The holmium-yttrium-aluminum garnet (Ho:YAG) laser has a wavelength of 2140 nm and is the only laser used in a pulsed mode of operation. It targets specifically water and water-containing tissue, leading to tissue coagulative necrosis in a 3 mm-4 mm area that results in a progressive sloughing of the prostatic tissue.<sup>15</sup> Treatment requires direct contact with tissue in order to create vaporization as the chromophore for laser energy is dominantly water. Different holmium systems offer different power outputs ranging from 20W to 120W, the 60W, 80W and 100W being the most commonly used for laser ablation of the prostate since the 120W laser is fairly new.

As previously mentioned, holmium laser can be used for different techniques: HoLRP (holmium laser resection of the prostate), HoLEP (holmium laser enucleation of the prostate) and HoLAP (holmium laser ablation of the prostate). Only HoLAP will be discussed in this chapter.

The first randomized trial on HoLAP was done by Mottet et al in 1999 and showed very similar early results between this technique (60W or 80W laser power) and TURP, but with the additional benefit of



**Figure 3.** Example of A) Holmium laser system: Lumenis Pulse 120H (120W power, 2100 nm). B) Thulium laser system: Revolix 200 (200W power, 2013 nm). C) Diode laser system: EVOLVE Dual system (150W power, combined 980 nm and 1470 nm). D) GreenLight laser system: LBO XPS (180W power, 532 nm).



a shorter catheterization time, less bleeding, and no initial dysuria and pain despite a more time-consuming procedure.<sup>16</sup> The long 7 year follow up data of the same population showed that the symptoms relief as well as the improvement of urinary function was durable; the re-treatment rate was 15%.<sup>17</sup> A retrospective study from 2013 showed that HoLAP done with a 100W laser is comparable to TURP regarding complications, re-treatment rate and symptomatic improvement in the long term.<sup>18</sup>

A recently published (2013) RCT in prostates smaller than 60 mL (mean of 33 mL) comparing HoLAP (60W) with GreenLight PVP using an 80W KTP showed that both procedures are equally effective and safe with comparable long term efficacy and symptoms improvement and a relatively longer operation time for HoLAP.<sup>19,20</sup> Retreatment rate at 5 years was even significantly lower in the HoLAP group (19.2% versus 25%). Thus, HoLAP has been shown to be a viable option to treat BPH for smaller prostates. However, regardless of the laser wavelength used, at least one of five patients required retreatment in this study, which is significantly higher than after TURP where the retreatment rate is considered to be 15% at 8 years.<sup>21</sup>

Currently, compared to the 2013 trial mentioned earlier, the newer and significantly improved generation of 532 nm lasers (120W and 180W) are available which provide better operative efficacy and more durable outcomes. Similarly newer generation of holmium system (Lumenis 120W) is now available but no outcomes of HoLAP using this newer technology have been reported in the literature to date.

#### *EAU guidelines recommendations<sup>1,8</sup>*

HoLAP is an alternative to TURP for small to medium-sized prostates. However, the holmium laser is now more commonly used for enucleation procedures, where it is actually considered the standard of care for larger prostates.

#### **Thulium: thulium vaporization of the prostate (ThuVAP)**

The thulium-YAG laser uses a very similar wavelength of 2013 nm in a continuous-wave mode, resulting in a shallow penetration (approximately 0.2 mm) allowing for smooth incision of prostatic tissue as well as effective and rapid vaporization.<sup>9</sup> This laser system is the most recently introduced, in 2005. Several different laser settings are used: the incision is usually done at a setting of 80W, while 120W or 150W are needed to perform vaporization.<sup>22</sup> Similar to the holmium laser, the target chromophore is water. Thulium lasers are

also typically used for resection and enucleation. Nevertheless, ThuVAP (thulium vaporization) is starting to draw more attention, but few institutions so far have published their results on this new modality.

Vargas et al showed high intraoperative safety with low rate of complications using the 150W thulium-YAG laser. They also showed excellent homeostasis and significant symptomatic improvement compared to baseline. All patients were discharged the same day and the catheter was removed 48 hours after the procedure.<sup>23</sup> Similar results were published by Pariser et al concerning both the 120W and the 150W systems.<sup>22</sup> The main drawback of this technique is the paucity of randomized controlled trials comparing it to TURP and/or open prostatectomy and the short term follow up.

#### *EAU guidelines recommendations<sup>1,8</sup>*

Further randomized clinical trials with long term follow up are required in order to compare ThuVAP with the standard of care and assess its long term efficacy as well as re-treatment rate before final conclusions are made.

#### **Diode**

A semi-conductor is used in order to generate the laser radiation. The former's material can be modified in order to change the wavelength of the laser, thus laser systems with a wavelength of 940 nm, 980 nm, 1318 nm and 1470 nm are available. Depending on the wavelength, the target chromophore can be either water or hemoglobin.<sup>24</sup> One of the newer diode laser systems is the Evolve 150W dual laser, which uses two different wavelengths (1470 nm and 980 nm). The advantage of this new laser is the addition of the 1470 nm wavelength allowing for increased affinity for water and thus increased safety, decreased postoperative symptoms, decreased energy per case, and faster procedure. This has yet to be confirmed in randomized control trials, but initial prospective study did show high safety and efficacy in the treatment of BPH with similar results to those expected with TURP.<sup>25</sup>

A retrospective study suggested comparable tissue ablation rates and lower bleeding rates between diode laser prostatectomy and GreenLight HPS, perhaps due to its higher tissue penetration.<sup>26</sup> It provides better intraoperative control of bleeding, especially for patients on anticoagulation therapy. However, it also leads to significantly higher re-treatment rate up to 35%, an increase incidence of bladder neck stricture, as well as temporary and permanent urinary incontinence compared to alternative treatments. The rate of dysuria and epididymitis was also significantly higher after diode laser prostatectomy.<sup>27,28</sup> Ruszat et al found

similar results in a prospective study comparing 200W diode prostatectomy and Greenlight HPS 120W: the former had better hemostasis at the cost of increased re-treatment rates and complications.<sup>29</sup>

In the past, the optical fibers used in diode prostatectomy were side-firing fiber. The new "Twister laser fiber" has been studied and was shown to decrease significantly postoperative complications.<sup>30</sup> A higher ablation efficiency and a higher resistance to degradation with these fibers were also reported.<sup>31</sup>

### *EAU guidelines recommendations<sup>1,8</sup>*

In light of these results, diode vaporization are not considered as a standard treatment option for BPH. Nevertheless, they are an alternative if the patient has a bleeding disorder or is anticoagulated.

### **GreenLight: photoselective vaporization of the prostate (PVP)**

The GreenLight laser is made by combining a neodymium:YAG laser resonator with a kalium-titanyl-phosphate (KTP) or a lithium triborate (LBO) crystal. This gives a laser with wavelength of 532 nm that is specifically absorbed by hemoglobin, and not by water. Three generations of GreenLight laser have been used in the recent years. The first generation is the 80W (KTP), followed by the 120W HPS (LBO) developed in 2006, and then came the 180W XPS (LBO) in 2010. It is the only laser system where extensive research has been conducted to compare the results obtained with different power outputs to each other. Today, the 180W XPS (LBO) system is the main one used due to increased power and increased area of laser beam (both by about 50%), allowing for more efficient vaporization while minimizing complications (namely capsular perforation or thermal tissue injury).<sup>32</sup> The vaporization depth is 0.8 mm to 3 mm with a 1 mm-2 mm rim of hemostatic coagulated tissue. GreenLight PVP is approved in international guidelines as an alternative to TURP with superior intraoperative safety and comparable functional results.<sup>1,33,34</sup>

Comparing the different neodymium:YAG laser, the 180W was shown to be more cost effective and to provide more efficient tissue removal due to a reduced operating and hospitalization time compared to the 120W laser.<sup>35</sup> Initially, the first system (80W KTP) showed significant improvement of voiding parameters at 12 months despite a re-treatment rate between 8.9%-14.8% (mainly due to adenoma, bladder neck and urethral strictures),<sup>36,37</sup> which was significantly higher than in patients undergoing TURP. Same results was shown with the 120W HPS laser,<sup>27</sup> mainly due to the inefficiency of immediate tissue

removal.<sup>38</sup> The GOLIATH study however showed that the re-intervention rate between XPS and TURP was similar and not statistically significant at 2 years of follow up: 9.0% for GreenLight XPS and 7.6% for TURP. A re-intervention rate three times higher after TURP in the first 30 days postop was however reported.<sup>39</sup> Overall, XPS was determined noninferior (comparable) to TURP in terms of complications and symptom improvement. The 2 year follow up confirmed that XPS is a durable surgical option for the treatment of LUTS in the context of BPH, with similar efficacy and outcomes.<sup>40</sup> Other descriptive analysis obtained the same results, making XPS a safe and effective option.<sup>41</sup> The main strength of GreenLight is its low bleeding rate, making it a safe and even a beneficial treatment option for high risk patients being anticoagulated.<sup>42-45</sup>

One of the additional advantages of the GreenLight 180W XPS (LBO) system is the availability of the MoXy fiber optic. This is a liquid-cooled, steel-caped fiber resulting in improved energy delivery, resulting in improved speed and efficiency of vaporization, while reducing tissue debris devitrification (i.e. crystallization of the fiber). The latter is the main culprit for fiber failure and decreased power delivery throughout the procedure.<sup>32</sup> Similar fibers for other laser systems have yet to be implemented. Thus, compared to the previous GreenLight generations, the latest XPS model has been shown to have improved efficiency by 30%-40% since both the speed of tissue removal (twice as fast as HPS) and the fiber longevity (often 1 fiber per case) is better.<sup>32</sup> Several published series have also demonstrated the significant improvement in treatment efficiency while maintaining safety.<sup>46,47</sup>

Originally used mainly in small prostate volumes, studies have suggested similar clinical results for patients with prostates greater than 80 cc. Energy usage superior to 4kJ/cc of the prostate volume assessed by transrectal ultrasound preoperatively and a postoperative drop of PSA superior than 50% have been suggested as landmark that reflect appropriate adenoma removal, and is associated with durable symptom improvement at 2 year follow up.<sup>48</sup> It is important to note that addressing larger prostates using Greenlight PVP requires expertise with the technique and that high conversion to TURP have been seen in these patients.

### *EAU guidelines recommendations<sup>1,8</sup>*

532 nm GreenLight vaporization is an alternative for patients with small to moderate glands causing BOO. It is also safe and effective for volume reduction in large prostates. Finally, it can be offered safely to patients taking anticoagulant medication and with a high cardiovascular risk.

TABLE 1. Best clinical data available for vaporization procedures for HoLAP, ThuVAP, diode vaporization and GreenLight PVP

Study Laser device/ technique	Patients n	Mean prostate size, mL	Mean operative time, min	Follow up month	PSA reduction -%	Mean change in symptoms (IPSS), -%	Change in Qmax mL/s (+%)	Retreatment rate, % (n)
Mottet et al <sup>16</sup> 1999								
<b>HoLAP</b>	23	39	75	12	n/a	65*	11.1 (226)	4.3 (1)
<b>TURP</b>	13	34	56		n/a	80*	9.6 (229)	15.4 (2)
Elmansy et al <sup>20</sup> 2010								
<b>HoLAP</b>	46	33	70	36	48	71	11.0 (264)	7 (4)
<b>80W KTP</b>	42	37	56		28	64	12.1 (289)	5.8 (4)
Pariser et al <sup>22</sup> 2014								
<b>ThuVAP</b> (120W or 150W)	59	57	35 (Lasing time)	3	38	56	9.4 (181)	0
Vargas et al <sup>23</sup> 2014								
<b>ThuVAP (150W)</b>	52	43	52	6	n/a	68	9.3 (105)	0
Ruszat et al <sup>29</sup> 2009								
<b>Diode</b> (980 nm, 200W)	55	65	56	6	58	76	5.1 (148)	18 (10)
<b>GreenLight</b> (LBO, 120W)	62	67	63		47	58	11.3 (191)	2 (1)
Chiang et al <sup>28</sup> 2010								
<b>Diode</b> (980 nm, 200W)	55	66	50 (Lasing time)	12	59	83	11.2 (204)	9.1 (5)
<b>GreenLight</b> (LBO, 120W)	84	60	50		42	84	15.0 (326)	3.6 (3)
Kim et al <sup>50</sup> 2013								
<b>Diode (980 nm)</b>	84	47	23	12	n/a	71	9.3 (206)	0
Chen et al <sup>51</sup> 2010								
<b>Diode (980 nm)</b>	55	66	50 (Lasing time)	6	59	76	13.7 (249)	7.3 (4)
GOLIATH, Thomas et al <sup>39</sup> 2015								
<b>GreenLight</b> (LBO, 180W)	128	49	50	24	48	67	12.1 (227)	9 (14)
<b>TURP</b>	121	46	39		58	73	13.0 (231)	7.6 (10)
Hueber et al <sup>48</sup> 2015								
<b>GreenLight</b> (LBO, 180W)	1196	61	55	24				1.2 (5)
< 80 cc at TRUS preop	387	50	45		54	72	11.9 (272)	
> 80 cc at TRUS preop	741	108	80		43	77	12.6 (327)	

\*AUA score was used in these studies instead of IPSS to assess symptomatic change.

AUA = American Urological Association; PSA = prostate-specific antigen; Qmax = maximum flow rate; HoLAP = holmium laser vaporization (ablation) of the prostate; n/a = not applicable; TURP = transurethral resection of the prostate; KTP = potassium titanyl phosphate; LBO = lithium borate; TRUS = transrectal ultrasound; ThuVAP = thulium vaporization of the prostate; IPSS = International Prostate Symptom Score. p value is only indicated if clinically and statistically significant.

## Comparative outcomes

The efficacy of the different laser systems based on the highest-quality clinical data is reviewed in Table 1. Shortcoming of comparison is the lack of head-to-head comparison of efficacy between technologies, patient age, prostate volume and surgical end-points (channel versus complete transition zone treatment down to capsule). Nevertheless, most reports demonstrate significant improvement in urinary parameters.

## Conclusion

In conclusion, laser based prostate ablation has allowed the urological community to offer minimally invasive surgery to BPH patients, particularly those with large prostates, anticoagulated men and those with significant age and comorbidity. With the improved hemostatic properties of laser technology, bleeding complications in several studies are significantly reduced. The most recent Greenlight PVP study, compared to TURP (GOLIATH trial), demonstrates this well.<sup>40</sup>

Although the current academic standard of care for BOO due to BPH is TURP for small to moderate prostate size and open prostatectomy for larger size prostate, laser procedures are now considered a safe alternative. This is even more important to consider in certain clinical scenarios, such as men on anticoagulation or antiplatelet therapy, with laser vaporization procedures being more advantageous. These techniques have thus to be patient-selected depending on their comorbidities.

Published outcomes for both GreenLight and HoLAP favor safety and mid-term durability, especially for small to mid-size prostates. For these reasons, the EAU and AUA recommends considering GreenLight PVP for patients receiving anticoagulants or those with a high cardiovascular risk. Similar results have been demonstrated for larger prostates (> 80 g), however usually with the addition of alternative laser techniques than pure vaporization (either vaporessection or vapoenucleation). Due to reasons of few reported outcomes on thulium and diode laser systems, coupled with important adverse outcomes related to deep tissue penetration with diode, these systems have not yet gained widespread acceptance nor recommendation as first-line treatment for BOO.

Moreover, greater use of transrectal ultrasonography to accurately measure prostate volume is still needed globally to predict operative parameters and properly counsel patients on treatment options and complications. The greatest experience thus far in the published literature come from holmium and Greenlight tissue vaporization – related to experience, learning curve and

favorable outcomes. Unfortunately, long term (5-10 year data) on treatment efficacy of all such lasers is greatly lacking. Further research is still needed to assess the durability of such technologies.

## Disclosure

Dr. Kevin Zorn is a paid consultant/proctor/lecturer for American Medical Systems.

Dr. Côme Tholomier, Dr. Roger Valdivieso and Dr. Pierre-Alain Hueber have no disclosures. □

## References

- Oelke M, Bachmann A, Descazeaud A et al. EAU guidelines on the treatment and follow-up of non-neurogenic male lower urinary tract symptoms including benign prostatic obstruction. *Eur Urol* 2013;64(1):118-140.
- Fraundorfer MR, Gilling PJ. Holmium:YAG laser enucleation of the prostate combined with mechanical morcellation: preliminary results. *Eur Urol* 1998;33(1):69-72.
- Lowrance WT, Southwick A, Maschino AC, Sandhu JS. Contemporary practice patterns of endoscopic surgical management for benign prostatic hyperplasia among urologists in the United States. *J Urol* 2013;189(5):1811-1816.
- Hueber PA, Zorn KC. Canadian trend in surgical management of benign prostatic hyperplasia and laser therapy from 2007-2008 to 2011-2012. *Can Urol Assoc J* 2013;7(9-10):E582-E586.
- Peyronnet B, Cornu JN, Roupert M, Bruyere F, Misrai V. Trends in the use of the GreenLight laser in the surgical management of benign prostatic obstruction in France over the past 10 years. *Eur Urol* 2015;67(6):1193-1195.
- McVary KT, Roehrborn CG, Avins AL et al. Update on AUA guideline on the management of benign prostatic hyperplasia. *J Urol* 2011;185(5):1793-1803.
- Gratzke C, Bachmann A, Descazeaud A et al. EAU guidelines on the assessment of non-neurogenic male lower urinary tract symptoms including benign prostatic obstruction. *Eur Urol* 2015;67(6):1099-1109.
- Herrmann TR, Liatsikos EN, Nagele U, Traxer O, Merseburger AS, EAU Guidelines Panel on Lasers Technologies. EAU guidelines on laser technologies. *Eur Urol* 2012;61(4):783-795.
- Bach T, Muschter R, Sroka R et al. Laser treatment of benign prostatic obstruction: basics and physical differences. *Eur Urol* 2012;61(2):317-325.
- Te AE. The next generation in laser treatments and the role of the GreenLight high-performance system laser. *Rev Urol* 2006;8(Suppl 3):S24-S30.
- Nazif OA, Teichman JM, Glickman RD, Welch AJ. Review of laser fibers: a practical guide for urologists. *J Endourol* 2004;18(9): 818-829.
- Hermanns T, Sulser T, Fatzer M et al. Laser fibre deterioration and loss of power output during photo-selective 80-w potassium-titanyl-phosphate laser vaporisation of the prostate. *Eur Urol* 2009;55(3):679-685.
- Issa MM. The evolution of laser therapy in the treatment of benign prostatic hyperplasia. *Rev Urol* 2005;7(Suppl 9):S15-S22.
- Westenberg A, Gilling P, Kennett K, Frampton C, Fraundorfer M. Holmium laser resection of the prostate versus transurethral resection of the prostate: results of a randomized trial with 4-year minimum long-term followup. *J Urol* 2004;172(2):616-619.
- Tan AH, Gilling PJ. Holmium laser prostatectomy. *BJU Int* 2003;92(6):527-530.



16. Mottet N, Anidjar M, Bourdon O et al. Randomized comparison of transurethral electroresection and holmium: YAG laser vaporization for symptomatic benign prostatic hyperplasia. *J Endourol* 1999;13(2):127-130.
17. Tan AH, Gilling PJ, Kennett KM, Fletcher H, Fraundorfer MR. Long-term results of high-power holmium laser vaporization (ablation) of the prostate. *BJU Int* 2003;92(7):707-709.
18. Jayadevan R, Stensland K, Baldwin G, Ali A, Hall S, Palese M. MP71-03 comparison of transurethral resection of prostate, PlasmaButton™ transurethral vaporization of prostate, GreenLight™ 180-W XPS photoselective vaporization of prostate, and Versapulse® 100-W holmium laser ablation of prostate. *J Urol* 191(4):e790.
19. Elshal AM, Elmansy HM, Elhilali MM. Two laser ablation techniques for a prostate less than 60 mL: lessons learned 70 months after a randomized controlled trial. *Urology* 2013;82(2):416-422.
20. Elmansy HM, Elzayat E, Elhilali MM. Holmium laser ablation versus photoselective vaporization of prostate less than 60 cc: long-term results of a randomized trial. *J Urol* 2010;184(5):2023-2028.
21. Madersbacher S, Lackner J, Brossner C et al. Reoperation, myocardial infarction and mortality after transurethral and open prostatectomy: a nation-wide, long-term analysis of 23,123 cases. *Eur Urol* 2005;47(4):499-504.
22. Pariser JJ, Famakinwa OJ, Pearce SM, Chung DE. High-power thulium laser vaporization of the prostate: short-term outcomes of safety and effectiveness. *J Endourol* 2014;28(11):1357-1362.
23. Vargas C, Garcia-Larrosa A, Capdevila S, Laborda A. Vaporization of the prostate with 150-w thulium laser: complications with 6-month follow-up. *J Endourol* 2014;28(7):841-845.
24. Bach T, Muschter R, Sroka R et al. Laser treatment of benign prostatic obstruction: basics and physical differences. *Eur Urol* 2012;61(2):317-325.
25. Muir G, Gomez F, Choi B, Erol A, Carmona L, Negro C. Multicentre prospective study of the Evolve: Dual 150W laser for bladder outflow obstruction: preliminary results. *Urology* 2011;78 (Suppl 3A):S59.
26. Wezel F, Wendt-Nordahl G, Huck N et al. New alternatives for laser vaporization of the prostate: experimental evaluation of a 980-, 1,318- and 1,470-nm diode laser device. *World J Urol* 2010;28(2):181-186.
27. Al-Ansari A, Younes N, Sampige VP et al. GreenLight HPS 120-W laser vaporization versus transurethral resection of the prostate for treatment of benign prostatic hyperplasia: a randomized clinical trial with midterm follow-up. *Eur Urol* 2010; 58(3):349-355.
28. Chiang PH, Chen CH, Kang CH, Chuang YC. GreenLight HPS laser 120-W versus diode laser 200-W vaporization of the prostate: comparative clinical experience. *Lasers Surg Med* 2010; 42(7):624-629.
29. Ruszat R, Seitz M, Wyler SF et al. Prospective single-centre comparison of 120-W diode-pumped solid-state high-intensity system laser vaporization of the prostate and 200-W high-intensity diode-laser ablation of the prostate for treating benign prostatic hyperplasia. *BJU Int* 2009;104(6):820-825.
30. Shaker HS, Shoeb MS, Yassin MM, Shaker SH. Quartz head contact laser fiber: a novel fiber for laser ablation of the prostate using the 980 nm high power diode laser. *J Urol* 2012;187(2):575-579.
31. Shaker H, Alokda A, Mahmoud H. The Twister laser fiber degradation and tissue ablation capability during 980-nm high-power diode laser ablation of the prostate. A randomized study versus the standard side-firing fiber. *Lasers Med Sci* 2012; 27(5):959-963.
32. Zorn KC, Liberman D. GreenLight 180W XPS photovaporization of the prostate: how I do it. *Can J Urol* 2011;18(5):5918-5926.
33. Hamann MF, Naumann CM, Seif C, van der Horst C, Junemann KP, Braun PM. Functional outcome following photoselective vaporisation of the prostate (PVP): urodynamic findings within 12 months follow-up. *Eur Urol* 2008;54(4):902-907.
34. Bouchier-Hayes DM, Anderson P, Van Appledorn S, Bugeja P, Costello AJ. KTP laser versus transurethral resection: early results of a randomized trial. *J Endourol* 2006;20(8):580-585.
35. Eken A, Soyupak B, Acil M, Arpacı T, Akbas T. Safety, efficacy and outcomes of the new GreenLight XPS 180W laser system compared to the GreenLight HPS 120W system for the treatment of benign prostatic hyperplasia in a prospective nonrandomized single-centre study. *Can Urol Assoc J* 2015;9(1-2):e56-e60.
36. Ruszat R, Seitz M, Wyler SF et al. GreenLight laser vaporization of the prostate: single-center experience and long-term results after 500 procedures. *Eur Urol* 2008;54(4):893-901.
37. Hai MA. Photoselective vaporization of prostate: five-year outcomes of entire clinic patient population. *Urology* 2009;73(4): 807-810.
38. Madersbacher S, Marberger M. Is transurethral resection of the prostate still justified? *BJU Int* 1999;83(3):227-237.
39. Thomas JA, Tubaro A, Barber N et al. A Multicenter randomized noninferiority trial comparing GreenLight-XPS laser vaporization of the prostate and transurethral resection of the prostate for the treatment of benign prostatic obstruction: two-yr outcomes of the GOLIATH study. *Euro Urol* 2015 Epub ahead of print.
40. Bachmann A, Tubaro A, Barber N et al. A European multicenter randomized noninferiority trial comparing 180 W GreenLight XPS laser vaporization and transurethral resection of the prostate for the treatment of benign prostatic obstruction: 12-month results of the GOLIATH study. *J Urol* 2015;193(2):570-578.
41. Plata M, Trujillo CG, Dominguez C et al. Photoselective vaporization with KTP 180-W Green laser for the treatment of lower urinary symptoms secondary to benign prostatic enlargement: effectiveness and safety at midterm follow-up. *J Endourol* 2015. Epub ahead of print.
42. Chung DE, Wysock JS, Lee RK et al. Outcomes and complications after 532 nm laser prostatectomy in anticoagulated patients with benign prostatic hyperplasia. *J Urol* 2011;186(3):977-981.
43. Ruszat R, Wyler S, Forster T et al. Safety and effectiveness of photoselective vaporization of the prostate (PVP) in patients on ongoing oral anticoagulation. *Eur Urol* 2007;51(4):1031-1038; discussion 8-41.
44. Bachmann A, Muir GH, Collins EJ et al. 180-W XPS GreenLight laser therapy for benign prostate hyperplasia: early safety, efficacy, and perioperative outcome after 201 procedures. *Eur Urol* 2012;61(3):600-607.
45. Sandhu JS, Ng CK, Gonzalez RR et al. Photoselective laser vaporization prostatectomy in men receiving anticoagulants. *J Endourol* 2005;19(10):1196-1198.
46. Hueber PA, Liberman D, Ben-Zvi T et al. 180 W vs 120 W lithium triborate photoselective vaporization of the prostate for benign prostatic hyperplasia: a global, multicenter comparative analysis of perioperative treatment parameters. *Urology* 2013;82(5):1108-1113.
47. Brunken C, Seitz C, Woo HH. A systematic review of experience of 180-W XPS GreenLight laser vaporisation of the prostate in 1640 men. *BJU Int* 2015;116(4):531-537.
48. Hueber PA, Bienz MN, Valdivieso R et al. Photoselective vaporization of the prostate for benign prostatic hyperplasia using the 180 Watt system: multicenter study of the impact of prostate size on safety and outcomes. *J Urol* 2015;194(2):462-469.
49. Elshal AM, Elkoushy MA, El-Nahas AR et al. GreenLight laser (XPS) photoselective vapo-enucleation versus holmium laser enucleation of the prostate for the treatment of symptomatic benign prostatic hyperplasia: a randomized controlled study. *J Urol* 2015;193(3):927-934.
50. Kim Y, Seong YK, Kim IG, Han BH. Twelve-month follow-up results of photoselective vaporization of the prostate with a 980-nm diode laser for treatment of benign hyperplasia. *Korean J Urol* 2013;54(10):677-681.
51. Chen CH, Chiang PH, Chuang YC et al. Preliminary results of prostate vaporization in the treatment of benign prostatic hyperplasia by using a 200-W high-intensity diode laser. *Urology* 2010;75(3):658-663.