

# *Ureteric re-implant for the strictured renal allograft: How I do it*

Thomas McGregor, MD,<sup>1</sup> Tadeuz Krocak, MD,<sup>1</sup> Chun Huang, MD,<sup>1</sup>  
Joshua Koulack, MD<sup>2</sup>

<sup>1</sup>Division of Urology, Department of Surgery, University of Manitoba, Winnipeg, Manitoba, Canada

<sup>2</sup>Division of Vascular Surgery, Department of Surgery, University of Manitoba, Winnipeg, Manitoba, Canada

---

MCGREGOR T, KROCZAK T, HUANG C, KOULACK J. Ureteric re-implant for the strictured renal allograft: How I do it. *Can J Urol* 2016;23(3): 8296-8300.

*Ureteric stricture is the most common urologic complication following renal transplantation. Initial treatment should consist of endoscopic management, however patients that fail endoscopic management or strictures that are not amendable to endoscopic management are appropriate candidates for open surgical repair. In this manuscript we*

*describe the steps and surgical technique we use to manage complicated ureteric strictures refractory to endoscopic management at our center. Ureteric re-implant with the use of a Boari flap is a safe, effective and definitive option for repair of ureteric strictures following renal transplantation. This approach provides excellent long term outcomes in terms of renal function preservation and negligible recurrence rates.*

**Key Words:** ureteric stricture, renal transplantation, surgical technique

---

## Introduction and patient selection

The most common urologic complication after renal transplant is ureteric stricture disease.<sup>1</sup> These patients often present with an acute worsening of renal function, allograft hydronephrosis and oliguria. Initial treatment should consist of endoscopic management utilizing a combination of stents and nephrostomy tubes. Endoscopic techniques provide for quick relief of obstruction with minimal risk to the allograft, but unfortunately have a high rate of failure long term. Patients that fail endoscopic management or strictures that are not amendable to endoscopic management are appropriate candidates for open surgical repair.<sup>2</sup> Open

surgical approaches yield the best long term outcomes and generally consist of ureteroneocystotomy with or without the use of a bladder flap.

In this manuscript we describe the steps and surgical technique we use to manage complicated ureteric strictures refractory to endoscopic management at our center.

Surgical technique, see Table 1 for key points

### *Preoperative preparation*

One week prior to surgery, if the patient does not already have one, an antegrade nephrostomy tube is placed into the allograft collecting system. Preoperative antibiotics and DVT prophylaxis are initiated the morning of surgery. Bowel preparation is not required.

### *Anesthesia and positioning*

Following a general anesthetic and line placement the patient is positioned in supine position with both arms extended. A 3-way Foley catheter is inserted to facilitate distension on the urinary bladder. Methylene Blue is diluted into a 500 mL volume of normal saline.

---

Accepted for publication March 2016

A fully narrated video demonstration of the technique is available online at [www.canjurol.com](http://www.canjurol.com)

Address correspondence to Dr. Thomas McGregor, Division of Urology, Department of Surgery, University of Manitoba, AD203-720 McDermot Avenue, Winnipeg, MB R3T 2N2 Canada

TABLE 1. Key points

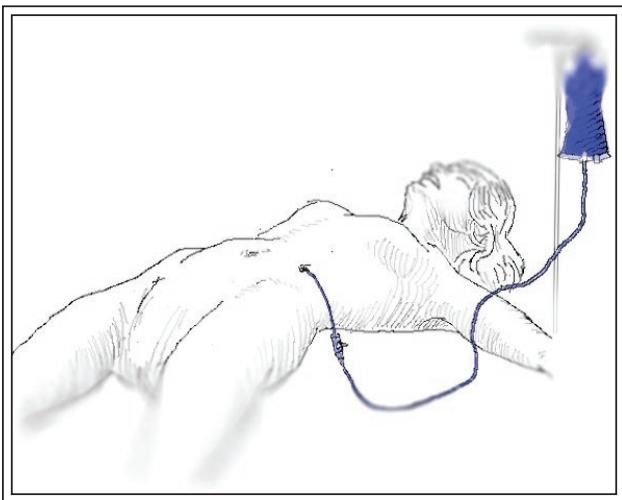
<b>Preoperative</b>	<ol style="list-style-type: none"> <li>1. Placement of nephrostomy tube one week prior to surgery.</li> <li>2. Perioperative antibiotic coverage.</li> <li>3. Placement of 3-way foley catheter for bladder distension.</li> </ol>
<b>Intraoperative</b>	<ol style="list-style-type: none"> <li>4. Infusion of methylene blue through nephrostomy tube to aid in collecting system identification.</li> <li>5. Use of seeker needle to assist with collecting system identification.</li> <li>6. Use of ultrasound to help identify and avoid injury to hilar vessels.</li> </ol>
<b>Postoperative</b>	<ol style="list-style-type: none"> <li>7. Systematic removal of indwelling tubes: <ol style="list-style-type: none"> <li>a) Foley catheter removal after 5-6 days</li> <li>b) JP drain removed if negative for urine after foley is removed</li> <li>c) Stent removal at 4-6 weeks</li> <li>d) Nephrostomy tube removal 1 week after stent removal.</li> </ol> </li> <li>8. Follow up lab work and allograft ultrasound to insure stable renal function and patency of ureteric re-implant.</li> </ol>

This is connected to the percutaneous nephrostomy tube and can be infused for identifying and confirming entry into the collecting system, Figure 1.

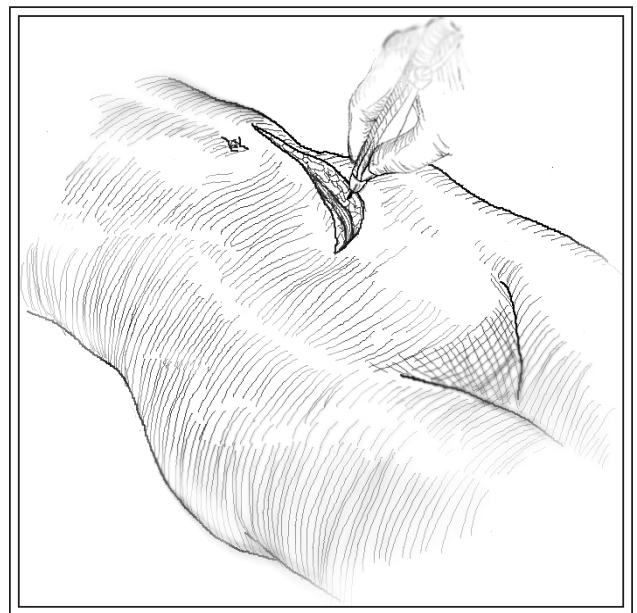
#### *Allograft dissection*

Once the patient is positioned and prepped, a Gibson incision is made over the allograft through the previous transplant incision, Figure 2. Dissection through the previous incision provides suitable exposure and cosmesis. The peritoneum is intentionally entered, a maneuver that affords avoidance scar tissue associated with the initial implant. The intra-peritoneal approach

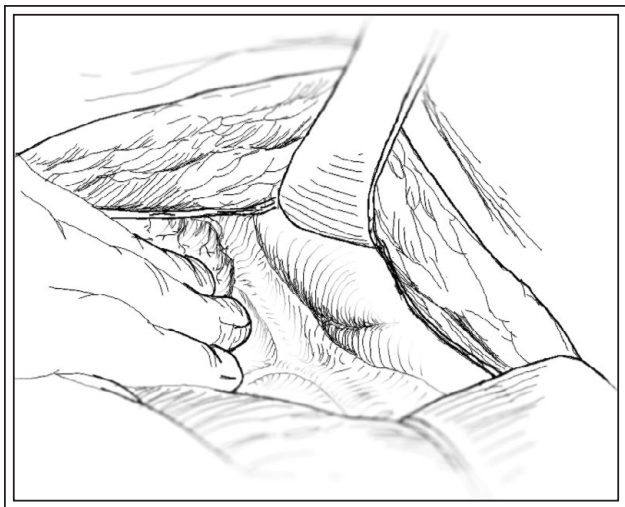
allows identification of allograft in the iliac fossa, with access to the hilar structures, Figure 3. The posterior leaf of the peritoneum is then incised and a thorough dissection towards the renal pelvis and vasculature is carried out. Depending on the degree of scarring, a length of ureter may be isolated, but often, only a portion of renal pelvis will be adequately mobilized, Figure 4. Confirmation of vasculature can be complemented by intraoperative ultrasound and direct palpation. Identification of the



**Figure 1.** Patient is placed in supine position. A nephrostomy tube has been placed preoperatively and methylene blue ready for infusion to aid in intraoperative identification of the collecting system.



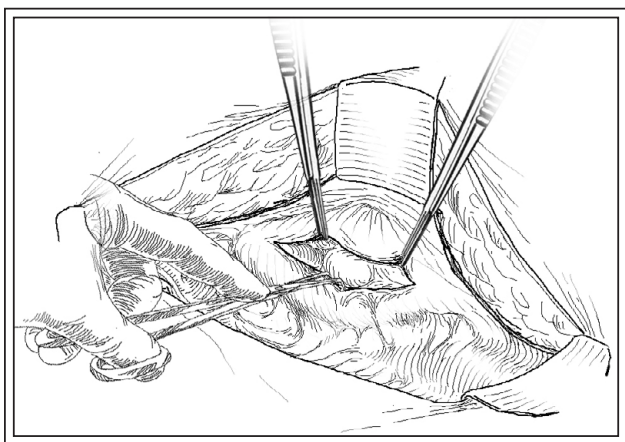
**Figure 2.** Access to the allograft is obtained through a Gibson incision. The peritoneum is intentionally entered.



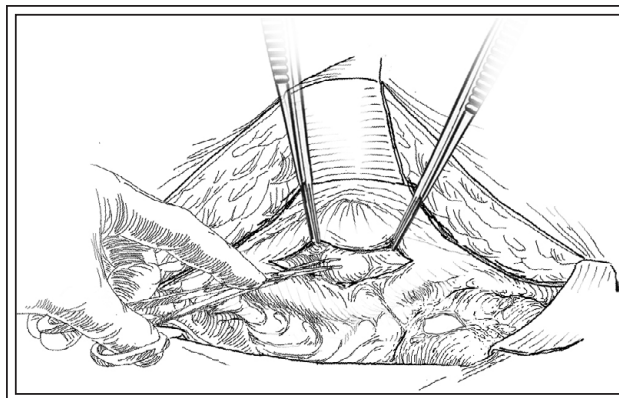
**Figure 3.** The peritoneum is entered and the posterior leaf can be seen overlying the allograft in the iliac fossa. This approach increases successful identification of the collecting system, avoids lengthy dissection through scar tissue, and allows easy access to the bladder later on for re-anastomosis.

renal pelvis can be facilitated by infusion of methylene blue through the antegrade nephrostomy tube. A 'seeker needle' (22-gauge) can be used to help identify and confirm location of the collecting system.

Once a healthy portion of proximal ureter or renal pelvis is isolated, a vertical incision is performed to create a pyelotomy. If a length of healthy ureter can be liberated at this point, it can be spatulated and used

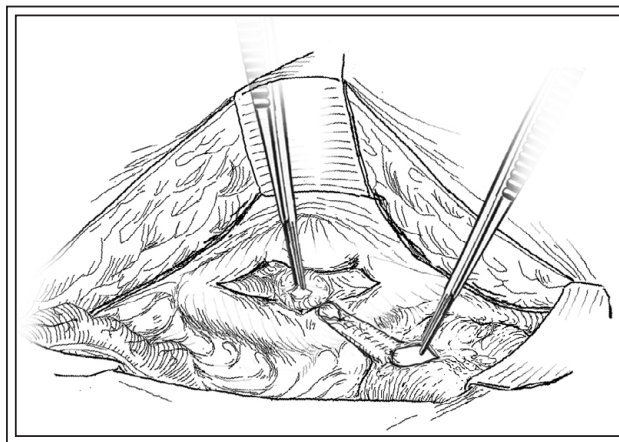


**Figure 4.** The posterior peritoneal layer is incised and careful dissection is carried out until the dilated renal pelvis is identified. Methylene blue is now infused and confirmation can be made by placing a finder needle into the bulging renal pelvis and aspirating the instilled fluid.



**Figure 5.** A vertical pyelotomy is created as well as a cystotomy. A Boari flap is then measured and raised. This is a highly variable process and decisions are made intraoperatively as to the size, location, and nature of the anastomosis.

for the anastomosis. The distance from the bladder to the dependent portion of the collecting system is then measured and a Boari flap is created to span this distance, Figure 5 and 6. The length of the flap can vary from case to case but often does not exceed a 5 cm-8 cm flap. Anastomosis between the bladder flap and allograft collecting system is then carried out in a spatulated, tension-free, water-tight fashion with 5-0 monofilament suture over a double-j stent. In our patients, a refluxing, direct anastomosis to the Boari flap is performed; however it has been described to perform a submucosal tunnel to achieve a non-refluxing ureteroneocystomy



**Figure 6.** The ureteric remnant or pyelotomy incision is then brought down to anastomose to the Boari flap. If a ureteric remnant can be obtained, this is spatulated and sutured to the bladder flap edges. Otherwise, an adequately sized pyelotomy would provide enough redundancy to successful bridging.

TABLE 2. Demographic data

Number of patients	12
Age (years)	51.5 (26-68)
Body mass index (kg/m <sup>2</sup> )	28.4 (21.2-42.8)
Charlson comorbidity index	4 (3-8)
Original cause of ESRD	5 DM, 2 PCKD, 2 GN, 1 FSGS, 1 HTN, 1 Alport's
Donor type	7 DD, 5 LD
Mean preop Cr (umol/L)	157 (94-328)
Mean preop eGFR (mL/min/1.73 m <sup>2</sup> )	41.8 (18.1-55.9)
Time to stricture (mons)	16.8 (0.5-96)
Stricture length (cm)	3 (2-4)
Time from diagnosis to open repair (mons)	55 (4-216)
Number of endoscopic interventions	12.7 (1-83)
Follow up (mons)	18

ESRD = end stage renal disease; DM = diabetes mellitus; GN = glomerulonephritis; HTN = hypertension; PCKD = autosomal dominant polycystic kidney disease; FSGS = focal segmental glomerulosclerosis; DD = deceased donor; LD = living donor

into the Boari flap itself.<sup>4</sup> The bladder is then closed in two layers, and can then be re-distended to confirm a water-tight closure. The peritoneum is then re-approximated and a Jackson-Pratt drain is placed on bulb suction. A consideration prior to closing the peritoneum and fascia is to perform a renal allograft biopsy with a core biopsy needle. Information gained from this biopsy can be quite useful in detecting the presence and degree of chronic rejection and can impact management of the patient's immunosuppressive regimen.<sup>3</sup>

#### Postoperative considerations

Hospital discharge often occurs within 5-6 days postoperatively. The foley catheter is left in place for 5 days, followed by drain removal 12 hours later if drain creatinine values remain normal. A cystogram is a consideration prior to catheter removal, although we do not routinely perform this. Patients are discharged home on 1 week of antibiotic coverage with the nephrostomy tube clamped and plans for stent removal in 3-4 weeks time. The capped nephrostomy

tube is removed 1week following stent removal if creatinine values remain stable.

Patients are then followed with serial Cr values over the first 6 months to insure stable renal function. Consideration is given to an ultrasound at the 6 month mark to insure absence of hydronephrosis and assess ureteric patency.

#### Results

We evaluated 12 consecutive ureteric re-implants after receiving approval from our institutional research ethics review board. All 12 re-implants were performed for complicated transplant ureteric strictures. Demographic data is represented in Table 2 and outcome data in Table 3. In ten of the twelve cases, the ureteric stricture was refractory to multiple attempts at endoscopic correction. The remaining two cases represented complete loss of the ureter at the level of the UPJ with no ability to pass wires or stents across the defect.

TABLE 3. Outcomes data

Length of stay (days)	7 (5-12)
Estimated blood loss (mL)	250 (50-400)
Complications	1 (revision of anastomosis at POD #4)
Postop Cr (umol/L) at 1 year follow up	142 (75-306)
Postop eGFR (mL/min/1.73 m <sup>2</sup> ) at 1 year follow up	48.6 (19.6-67.9)
Stricture recurrences at 1 year follow up	nil

In all cases a Boari flap was utilized to span the distance from the bladder to healthy renal allograft collecting system. Despite the severe scarring that usually surrounds a renal transplant, there were no intra-operative complications experienced, including no injury to renal hilar vessels and no allograft loss. There was only one post-operative complication experienced in the form of a revision of an anastomosis at POD #4 to correct kinking from a redundant Boari flap. As shown in Table 3, outcomes were very reasonable with renal function being salvaged in all cases.

## Discussion

Ureteric stricture is the most common urologic complication following renal transplant.<sup>1</sup> Most transplant series describe a stricture rate between 1%-5% depending on the type of donor, recipient comorbidities and anastomotic technique.<sup>5,6</sup> Initial management of an obstructed renal allograft secondary to a ureteric stricture needs to be quick to restore urine drainage and allow for immediate improvement in renal function to prevent long term obstructive uropathy effects.<sup>7</sup> Long term, however, endoscopic management can yield high failure rates with the need for multiple repeat procedures.<sup>8</sup> Hence, for recurrent strictures or strictures not amendable to endoscopic correction, open surgical repair is the best option as it offers a definitive repair with excellent long-term outcomes.<sup>2,9</sup>

Although open surgery on a renal allograft can be complicated by scarring and adhesions associated with the original surgery; a careful and planned approach, such that we describe here allows for a safe and effective dissection. Our approach utilizes a couple clever techniques to help prevent both vascular and urinary complications, these being the use of intra-operative ultrasound to identify hilar vessels and use of a seeker needle to identify the distended renal pelvis. As shown in our results, we experienced no intraoperative complications as a result.

The use of a Boari flap provides a well vascularize conduit to span the gap between the bladder and allograft collecting system. The Boari flap is robust, and can be fashioned to span distances between 5 cm-15 cm in length.<sup>10</sup> As shown in our series, this gap often does not exceed 10cm due to the pelvic location of the renal allograft.

Lastly, this approach to repair renal allograft ureteric strictures yields excellent long term results. In all 12 cases we describe, allograft function was preserved and there were no recurrences at greater than 1 year follow up. Other reports in the literature utilizing a bladder flap describe similar excellent long term outcomes.<sup>8,9</sup>

## Conclusion

Ureteric reimplant with the use of a Boari flap is a safe, effective and definitive option for repair of ureteric strictures following renal transplantation. This approach provides excellent long term outcomes in terms of renal function preservation and negligible recurrence rates. □

---

## References

1. Hau HM, Tautenhahn HM, Schmelzle M et al. Management of urologic complications in renal transplantation: a single-center experience. *Transplant Proc* 2014;46(5):1332-1339.
2. Krocak T, Koulack J, McGregor T. Management of complicated ureteric strictures after renal transplantation: case series of pyelovesicostomy with Boari flap. *Transplant Proc* 2015;47(6):1850-1853.
3. Rush D, Nickerson P, Jeffery J. Protocol biopsies in the management of renal allograft recipients. *Curr Opin Nephrol Hypertens* 2000;9(6):615-619.
4. Del Pizzo JJ, Jacobs SC, Bartlett ST, Sklar GN. The use of bladder for total transplant ureteral reconstruction. *J Urol* 1998;159(3):750-753.
5. Baston C, Harza M, Preda A et al. Comparative urologic complications of ureteroneocystostomy in kidney transplantation: transvesical Leadbetter-Politano versus extravesical Lich-Gregoir technique. *Transplant Proc* 2014;46(1):176-179.
6. Alberts VP, Idu MM, Legemate DA, Laguna Pes MP, Minnee RC. Ureterovesical anastomotic techniques for kidney transplantation: a systematic review and meta-analysis. *Transpl Int* 2014;27(6):593-605.
7. Tillou X, Raynal G, Demailly M, Hakami F, Saint F, Petit J. Endoscopic management of urologic complications following renal transplantation: impact of ureteral anastomosis. *Transplant Proc* 2009;41(8):3317-3319.
8. Giessing M. Transplant ureter stricture following renal transplantation: surgical options. *Transplant Proc* 2011;43(1):383-386.
9. Azhar RA, Hassanain M, Al Jiffry M et al. Successful salvage of kidney allografts threatened by ureteral stricture using pyleovesical bypass. *Am J Transplant* 2010;10(6):1414-1419.
10. Mauck RJ, Hudak SJ, Terlecki RP, Morey AF. Central role of Boari bladder flap and downward nephropexy in upper ureteral reconstruction. *J Urol* 2011;186(4):1345-1349.