

# Focal bladder neck cauterization associated with low rate of post-Aquablation bleeding

Dean S. Elterman, MD,<sup>1</sup> Susan Foller, MD,<sup>2</sup> Burkhard Ubrig, MD,<sup>3</sup> Alexander Kugler, MD,<sup>4</sup> Vincent Misrai, MD,<sup>5</sup> Angelo Porreca, MD,<sup>6</sup> Dominik Abt, MD,<sup>7</sup> Kevin C. Zorn, MD,<sup>8</sup> Naeem Bhojani, MD,<sup>8</sup> Lewis Kritek, MD,<sup>9</sup> Rahul Mehan, MD,<sup>10</sup> Michael McDonald, MD,<sup>11</sup> Steven A. Kaplan, MD<sup>12</sup>

<sup>1</sup>Division of Urology, University Health Network, University of Toronto, Toronto, Ontario, Canada; <sup>2</sup>Universitätsklinikum Jena, Jena, Germany; <sup>3</sup>Witten/Herdecke University, Augusta-Kranken-Anstalt, Bochum, Germany; <sup>4</sup>Klinikum Fichtelgebirge Marktredwitz gGmbH, Marktredwitz, Germany; <sup>5</sup>Clinique Pasteur, Toulouse, France; <sup>6</sup>Policlinico Abano Terme, Abano Terme PD, Italy; <sup>7</sup>Kantonsspital St. Gallen, Switzerland; <sup>8</sup>University of Montreal, Montreal, Quebec, Canada; <sup>9</sup>Northside Forsyth Hospital, Atlanta, Georgia, USA; <sup>10</sup>East Valley Urology Center, Mesa, Arizona, USA; <sup>11</sup>AdventHealth Celebration, Celebration, Florida, USA; <sup>12</sup>Mount Sinai Medical Center, New York, New York, USA

ELTERMAN DS, FOLLER S, UBRIG B, KUGLER A, MISRAI V, PORRECA A, ABT D, ZORN KC, BHOJANI N, KRITEMAN L, MEHAN R, MCDONALD M, KAPLAN SA. Focal bladder neck cauterization associated with low rate of post-Aquablation bleeding. *Can J Urol* 2021;28(2):10610-10613.

**Introduction:** To determine if focal bladder neck cauterization is effective in reducing bleeding following prostate tissue resection for benign prostatic hyperplasia using Aquablation.

**Materials and methods:** Consecutive patients at 11 countries in Asia, Europe and North America who underwent Aquablation for symptomatic benign prostatic hyperplasia between late 2019 and January 2021 were included in the analysis. All patients received post-Aquablation non-resective focal cauterization at the bladder neck.

**Results:** A total of 2,089 consecutive Aquablation procedures were included. Mean prostate size was 87 cc (range 20 cc to 363 cc). Postoperative bleeding requiring transfusion occurred in 17 cases (0.8%, 95% CI 0.5%-1.3%) and take-back to the operating room for fulguration occurred in 12 cases (0.6%, 95% CI 0.3%-1.0%). This result compares favorably ( $p < .0001$ ) to the previously published hemostasis transfusion rate of 3.9% (31/801) using methods performed in the years 2014 to 2019.

**Conclusions:** In prostates sizes averaging 87cc (range 20 cc-363 cc), Aquablation procedures performed with focal bladder neck cauterization that required a transfusion postoperatively occurred in a remarkably low number of cases.

**Key Words:** Aquablation therapy, benign prostatic hyperplasia, transfusions, lower urinary tract symptoms, robotic, focal bladder neck cauterization

## Introduction

Several techniques are available for the surgical treatment of symptomatic benign prostatic hyperplasia (BPH). While both tissue-removing (resective) and non tissue-removing (non-resective) approaches to BPH treatment are effective, it is generally acknowledged

that resective techniques are both more effective and carry a higher risk of perioperative adverse events.

Robotically executed, image-guided waterjet-based tissue removal (Aquablation Therapy) is a recent addition to available BPH surgical therapeutic options. The safety and effectiveness of Aquablation compared to the current gold standard (transurethral resection of the prostate (TURP)) have been demonstrated in a large blinded international randomized trial.<sup>1,2</sup>

An inherent limitation of the athermal Aquablation procedure is the absence of a direct method to achieve post-resection hemostasis. In a small number of cases during the pivotal trials, this resulted in the need for

Accepted for publication March 2021

Address correspondence to Dr. Dean S. Elterman, Toronto Western Hospital, Main Pavilion, 8<sup>th</sup> Floor, Room 317, 399 Bathurst Street, Toronto, ON M5T 2S8 Canada

transfusion and/or takeback to the operating room for hemostasis. Perceptions of a bleeding problem associated with Aquablation have limited, to some extent, its uptake in the community. In earlier studies, various methods to achieve hemostasis were tried, including balloon tamponade, robust balloon traction at the bladder neck, alternative techniques for bladder washout and postoperative bladder irrigation, and hemostatic agents, none of which appeared to reliably reduce post-resection bleeding. In WATER II, a prospective single-arm trial of Aquablation for larger prostates (80 cc-150 cc), balloon tamponade without electrocautery was associated with a 9.9% rate of transfusion.<sup>3</sup> In an analysis combining results from premarket trials and early commercial experience, we observed a transfusion rate of 3.9%.<sup>4</sup> Larger prostate volumes (> 77 cc) were associated with a higher transfusion rate. Additionally, the use of robust balloon catheter traction, which aimed to provide tamponade at the bladder neck, appeared to show higher transfusion rates while standard traction combined with the use of non-resective focal bladder neck cauterization (FBNC) following Aquablation was associated with lower transfusion rates.

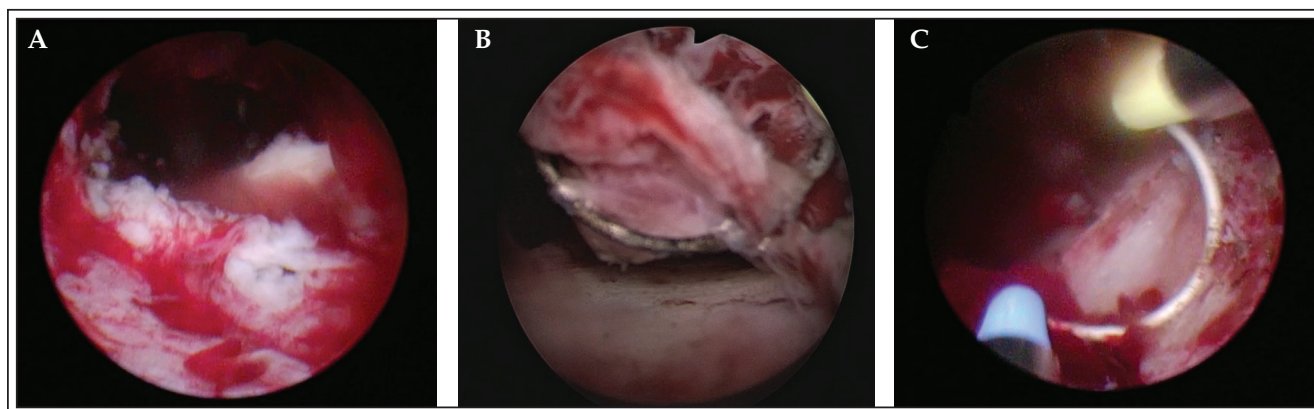
As FBNC following Aquablation appeared promising for achieving rapid hemostasis, this practice was adopted in late 2019. Herein we report a multicenter, retrospective analysis of transfusion rates associated with the use of this technique.

## Materials and methods

In 2019, surgeons noticed that FBNC was effective in obtaining rapid post-Aquablation hemostasis. Aquablation is a surgical therapy using real-time

ultrasound imaging and a delivery of a precise, automated, robotically executed high velocity waterjet to ablate prostate adenoma tissue. Following the waterjet ablation, the surgeon removes the AQUABEAM (PROCEPT BioRobotics, Redwood City, CA, USA) handpiece and introduces a standard resectoscope sheath along with a monopolar or bipolar loop to perform FBNC.

The rationale for FBNC was as follows. The Aquablation procedure removes prostate tissue, leaving a prostate cavity comprised of tissue remnants, Figure 1A. The remnant tissue has a cloud-like “fluffy” appearance that is 8 mm-15 mm in depth,<sup>1,3</sup> substantially larger than the depth of a resectoscope loop (4 mm). Effective cauterization at the bladder neck first requires removal of this fluffy tissue, Figure 1B and 1C, to access deeper bleeding vessels. Cautery of just fluffy tissue would likely not achieve hemostasis and cause continued bleeding in postoperative recovery. After removal of fluffy tissue, the surgeon can then easily identify bleeding vessels and effectively cauterize them. Note this cauterization is non-resective; it does not remove substantial prostate tissue (already removed through Aquablation). Standard postoperative catheter management and irrigation was used in this series. The catheter tensioning device described in previous publications was not used and has not been commercially available since mid 2019. The use of FBNC appeared to allow both a smooth transition from the OR to the postoperative care unit and ward and discharge from the hospital the next morning in most cases. Accordingly, 21 surgeons began to use this technique in standard clinical practice in late 2019. By the beginning of 2020, FBNC was adopted by nearly all surgeons performing Aquablation procedures.



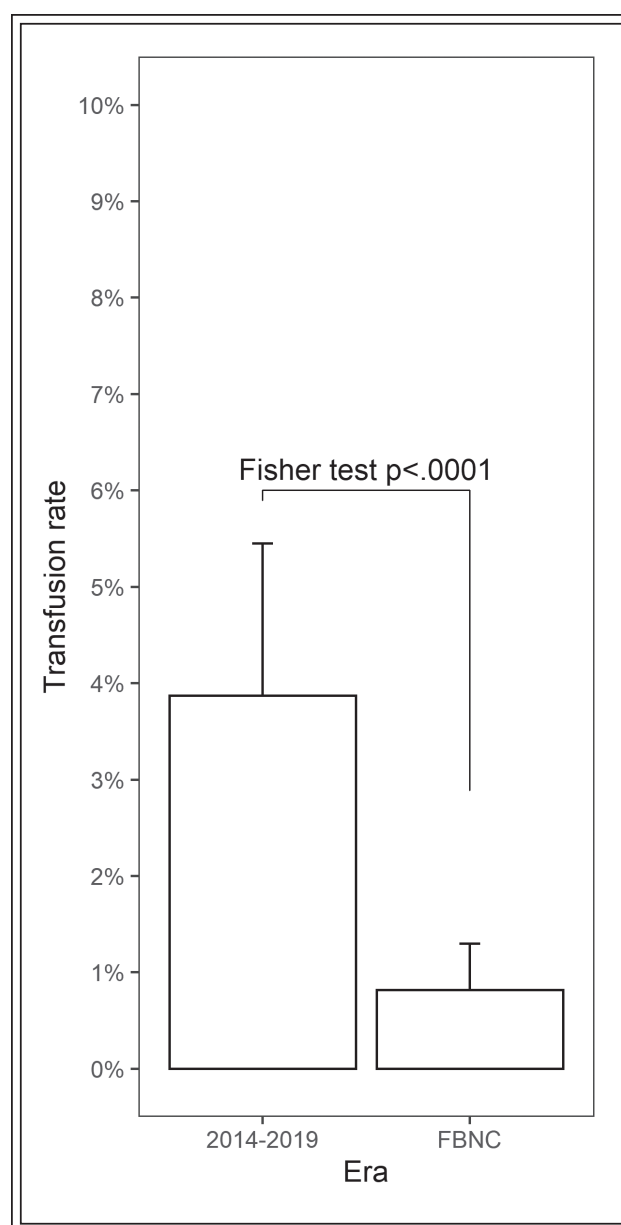
**Figure 1.** (A) Appearance of bladder neck immediately following Aquablation. Commonly observed is “fluffy” tissue. (B) Use of loop to remove fluffy tissue. (C) Cauterizing the surface of the bladder neck. Note that the loop is not used to resect additional prostate tissue that was not ablated with the waterjet.

As part of common postmarket surveillance, the device manufacturer tracks Aquablation procedures. Information collected from each procedure included procedure date, surgeon name, prostate size, and occurrence of potentially reportable complaints and postoperative events. Such tracking is commonly used by manufacturers for required postmarket complaints and adverse events assessment and reporting per medical device regulations in the US, EU and other geographies. The manufacturer identified all surgeons using FBNC after Aquablation during the time period of interest (late 2019 to January 2021). Aquablation training using FBNC was implemented globally January 2020. Data from all cases performed with FBNC were analyzed. Surgeons performing cases report to the manufacturer the occurrence of post-procedure transfusion and take-backs to the operating room, among other complaints/events. We report the proportion of patients undergoing transfusions along with exact 95% exact confidence limits. Fisher's test was used to compare the proportion of patients requiring transfusion after FNBC versus those reported in an earlier report.<sup>4</sup>

## Results

Between late 2019 and January 2021, 2,089 Aquablation cases were performed using FBNC in 11 countries from Asia, Europe, and North America by 170 surgeons. The mean (SD) prostate size was 87 cc  $\pm$  44 cc (range 20 cc to 363 cc). The average time spent after removing the handpiece to inserting the urinary catheter was 19.9 minutes  $\pm$  10.9 minutes. This segment of the procedure includes flushing, transitioning to the resectoscope, cauterizing at the bladder neck, and final flushing.

Postoperative bleeding requiring transfusion occurred in 17 cases (0.8%, 95% CI 0.5%-1.3%). This result compares favorably ( $p < .0001$ ) to the previously published hemostasis aggregate transfusion rate of 3.9% (31/801) using methods performed in the years 2014 to 2019,<sup>4</sup> Figure 2. In the 17 transfusions reported, none occurred beyond 3 days post-Aquablation treatment and the average number of units given was two. Four



**Figure 2.** Comparison of transfusion rates from previously published data for procedures performed in 2014-2019<sup>4</sup> versus the current series of 2,089 Aquablation procedures using focal bladder neck cautery (FBNC).

**TABLE 1. Transfusion rates across various BPH resective modalities**

	TURP <sup>9,10</sup>	PVP <sup>11</sup>	Enucleation <sup>12,13</sup>	Open simple prostatectomy <sup>12,13</sup>	Aquablation <sup>4</sup> (previous series)	Aquablation (current series)
Prostate volume*	56-131 cc	65 cc	54-126 cc	84-124 cc	67 cc	87 cc
Transfusions (%)	4-14%	2.1%	0-5%	0-24%	3.9%	0.8%

\*mean or range of means if multiple sources referenced; TURP = transurethral resection of prostate; PVP = photoselective vaporization of the prostate

(24%) of the 17 transfusions occurred in patients who were on an anticoagulant or antiplatelet therapy. The average prostate volume was 109 cc ± 37 cc. Eighty-eight percent (88%) of the transfusions occurred before a surgeon's sixth Aquablation procedure. Take-backs to the operating room for fulguration to address bleeding occurred in 12 cases (0.6%, 95% CI 0.3%-1.0%), which compared favorably to the previous era of 4.4% (35/801).

## Discussion

While safe and effective for the treatment of lower urinary tract symptoms due to BPH across a broad range of prostate sizes,<sup>1,5-8</sup> the Aquablation procedure does not include a direct mechanism to achieve hemostasis. This limitation inspired the use of a variety of methods to conveniently and rapidly achieve post-Aquablation hemostasis, with variable results. Given that cauterization is a well-known, well-understood, and commonly used surgical technique, its use and effectiveness is not surprising. The observed rate of transfusion when using FBNC for hemostasis was only 0.8%, which compares favorably to previous estimates (3.9%) prior to the use of this technique.<sup>4</sup> The low transfusion rate is remarkable given the large mean prostate size (87 cc) and the inclusion of some very large (> 300 cc) prostates. The rate also compares favorably to reports of transfusion rates with TURP,<sup>9,10</sup> PVP,<sup>11</sup> enucleation,<sup>12,13</sup> and open simple prostatectomy<sup>12,13</sup> in large prostates, Table 1.

Given the simplicity of FBNC and its associated low rate of postoperative transfusion, the authors suggest that use of FBNC makes Aquablation a safe treatment option for BPH across a wide range of prostate sizes and shapes.

Limitations of our study include the following. First, this was a retrospective analysis. Second, there is no clear threshold for need for transfusion; some of the decreased rate could have been related to surgeons' increasing comfort with mild post-Aquablation bleeding. Third, it is unknown whether all transfusions were clinically necessary. Nonetheless, the reduction in the rate of post-Aquablation transfusion is remarkable. Given its simplicity and apparent effectiveness, it seems a reasonable approach for hemostasis until alternative means are discovered.

## Conclusion

In prostates sizes averaging 87cc (range 20 cc-363 cc), Aquablation procedures performed with FBNC that required a transfusion postoperatively occurred in a remarkably low number of cases.

## Disclosure

D. Elterman, S. Foller, B. Ubrig, V. Misrai, A. Porreca, D. Abt, K. Zorn, N. Bhojani, L. Kriteman, R. Mehan, and M. McDonald had in the past or currently have a consulting agreement with PROCEPT BioRobotics.

## Funding

There was no funding provided for this research. □

---

## References

1. Gilling P, Barber N, Bidair M et al. WATER: A double-blind, randomized, controlled trial of Aquablation® vs. transurethral resection of the prostate in benign prostatic hyperplasia. *J Urol* 2018;199(5):1252-1261.
2. Gilling P, Barber N, Bidair M et al. Three-year outcomes after Aquablation therapy compared to TURP: results from a blinded randomized trial. *Can J Urol* 2020;27(1):10072-10079.
3. Desai M, Bidair M, Bhojani N et al. WATER II (80-150 mL) procedural outcomes. *BJU Int* 2019;123(1):106-112.
4. Elterman D, Bach T, Rijo E et al. Transfusion rates after 800 Aquablation procedures using various hemostasis methods. *BJU Int* 2020;125(4):568-572.
5. Bhojani N, Bidair M, Zorn KC et al. Aquablation for benign prostatic hyperplasia in large prostates (80-150 cc): 1-year results. *Urology* 2019;129:1-7.
6. Bach T, Giannakis I, Bachmann A et al. Aquablation of the prostate: single-center results of a non-selected, consecutive patient cohort. *World J Urol* 2019;37(7):1369-1375.
7. Misrai V, Rijo E, Zorn KC, Barry-Delongchamps N, Descazeaud A. Waterjet ablation therapy for treating benign prostatic obstruction in patients with small- to medium-size glands: 12-month results of the first French Aquablation clinical registry. *Eur Urol* 2019;76(5):667-675.
8. Bach T, Gilling P, El Hajj A, Anderson P, Barber N. First multicenter all-comers study for the Aquablation procedure. *J Clin Med* 2020;9(2):603.
9. Fagerström T, Nyman CR, Hahn RG. Bipolar transurethral resection of the prostate causes less bleeding than the monopolar technique: a single-centre randomized trial of 202 patients. *BJU Int* 2010;105(11):1560-1564.
10. Ou R, You M, Tang P, Chen H, Deng X, Xie K. A randomized trial of transvesical prostatectomy versus transurethral resection of the prostate for prostate greater than 80 mL. *Urology* 2010;76(4):958-961.
11. Law K, Tholomier C, Couture F et al. PD61-07 Global Greenlight group: largest international Greenlight experience for benign prostatic hyperplasia. *J Urol* 2020;203(Suppl 4):e1282.
12. Gratzke C, Schlenker B, Seitz M et al. Complications and early postoperative outcome after open prostatectomy in patients with benign prostatic enlargement: results of a prospective multicenter study. *J Urol* 2007;177(4):1419-1422.
13. Aho TF. Holmium laser enucleation of the prostate: a paradigm shift in benign prostatic hyperplasia surgery. *Ther Adv Urol* 2013;5(5):245-253.