

# *How I Do It: The Optilume drug-coated balloon for urethral strictures*

Dean S. Elterman, MD,<sup>1</sup> Karl Coutinho, MD,<sup>2</sup> Judith C. Hagedorn, MD<sup>3</sup>

<sup>1</sup>Division of Urology, Department of Surgery, University of Toronto, Toronto, Ontario, Canada

<sup>2</sup>New Jersey Urology, Millburn, New Jersey, USA

<sup>3</sup>Department of Urology, University of Washington, Seattle, Washington, USA

---

ELTERMAN DS, COUTINHO K, HAGEDORN JC.  
How I Do It: The Optilume drug-coated balloon for urethral strictures. *Can J Urol* 2020;27(4):10322-10328.

*Urethral stricture disease can be difficult to treat and stricture recurrence is common. The management of stricture disease has evolved and urethroplasty can achieve a high rate of lasting urethral patency. Nevertheless, endoscopic treatments still seem to have sub-optimal outcomes with high stricture recurrence rates. The*

*Optilume drug-coated balloon represents a step forward in the endoscopic management of urethral strictures. The drug-coated balloon may offer an intermediate step prior to repeated dilations, urethrostomies, or urethroplasty. This treatment modality is a promising alternative to current endoscopic management and an option for patients that are poor surgical candidates or decline urethroplasty.*

**Key Words:** urethral stricture, urethral dilation, drug-coated balloon

---

## Introduction

### *Overview of procedure/technology*

Urethral stricture disease is a prevalent and challenging urological condition that has been described for thousands of years. Although stricture management has evolved over the last century to include endoscopic treatments and urethroplasty, patients have not yet had a durable, minimally invasive solution, as recurrence rates approach 100% after two prior endoscopic procedures.<sup>1-4</sup>

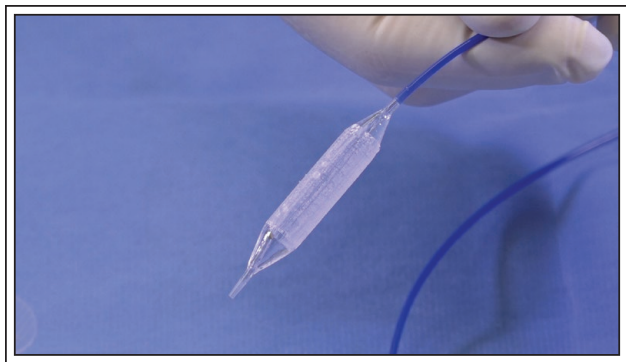
The Optilume (Urotronic, Plymouth, MN, USA) drug-coated balloon, Figure 1, is a minimally invasive urethral stricture treatment developed in response to demand for improved solutions for endoscopic stricture management. This proprietary technology combines balloon dilation and drug delivery (paclitaxel). The Optilume procedure is well tolerated by patients and has shown promising early data in clinical trials.<sup>5</sup>

Paclitaxel is a proven antiproliferative drug that has been used in chemotherapy since the early 1990's and percutaneous coronary interventions since 2004. Since that time, it has been effectively used in millions of patients worldwide, in various applications. As a mitotic inhibitor, paclitaxel's mechanism of action works by preventing cell division and proliferation, stopping new tissue growth and preventing fibrotic scarring that leads to stricture recurrence.

---

Accepted for publication July 2020

Address correspondence to Dr. Dean S. Elterman, Toronto Western Hospital, Main Pavilion, 8<sup>th</sup> Floor, Room 317, 399 Bathurst Street, Toronto, ON M5T 2S8 Canada



**Figure 1.** Optilume, drug-coating can be seen as whitish layer in mid portion of balloon.

### *Relevant historical studies*

In the early 1990's, Heyns and Steenkamp conducted a prospective, randomized trial examining the failure rates of endoscopic treatments for urethral stricture.<sup>6</sup> Between January 1991 and January 1994, 210 men with diagnosed urethral strictures were prospectively randomized to undergo filiform dilation (106) or direct vision internal urethrotomy (DVIU) (104). Dilation or DVIU were repeated at the first and second stricture recurrence, if they occurred. One hundred and sixty-three patients were ultimately followed with a mean of 24 months. The stricture-free rate at 6 months was 80% for a first or second treatment, and 20% for a third treatment. At 24 months, the stricture-free rate was 60% for the first treatment, 20% for the second treatment and 0% for the third.

Adjunctive intralesional drugs have been investigated by a number of groups. A randomized controlled trial of 70 patients used corticosteroid injection (triamcinolone) in the treatment arm and sterile water in the control arm.<sup>7</sup> The recurrence rate was no different in the two study arms at 12 months. A case series of DVIU with hyaluronic acid injection showed no difference with historical controls.<sup>8</sup> A multicenter, randomized trial did show initial benefits from a hyaluronic acid injection at the time of DVIU, but the study lacked long term follow up.<sup>9</sup>

In 2012, a review of the literature examining long term effects of urethral dilation, showed that endoscopic management is by far the most common treatment for urethral strictures even with poor evidence of the long term efficacy.<sup>2</sup> The outcomes for internal urethrotomy are largely affected by the duration of follow up after the endoscopic procedure. Recurrence rates are 35% at 12 months, but as high as 79% at 36 months for DVIU.<sup>2</sup> The authors conclude that endoscopic management of urethral strictures has

a short-lived symptom improvement with up to 90% recurrence with long term follow up.

Hence, the development of a more effective and lasting endoscopic treatment for urethral strictures is much needed. The Optilume drug-coated balloon (DCB) offers a step forward in the improvement of endoscopic outcomes.

Although this is the first study conducted using a paclitaxel-DCB for urethral strictures, several other studies have investigated other drugs in conjunction with mechanical dilation. A recent study demonstrated 75% patency at 2 years following DVIU with MMC injection and self-dilation; but, significant adverse effects have been reported after MMC injection into urinary mucosa. Outcomes with urethral triamcinolone as an adjuvant vary widely between studies. The Optilume DCB may offer advantages compared to these other adjuvants. First, as a hydrophobic drug it absorbs easily into the target tissue avoiding immediate washout. Second, the half-life of paclitaxel is measured in days whereas the half-life of MMC is hours. This allows paclitaxel to be present during the inflammatory, proliferation and remodeling stages of wound healing. Third, the paclitaxel dosing is tightly controlled by the proprietary DCB coating process, avoiding the risks of overdosing with manual injection. Fourth, paclitaxel is circumferentially delivered topically to the urothelium, reducing the risk of periurethral dosing that can occur with deep injections.<sup>10</sup>

### Method and technique

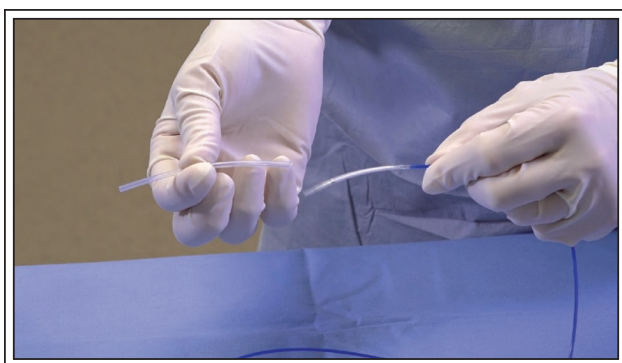
A thorough evaluation of the urethra to characterize the stricture is the first step that must be taken prior to performing the Optilume procedure. A detailed history of the nature of the mechanism of injury, timeline from incident event to formation of the stricture as well as any interventions should be reviewed. Details of each prior stricture treatment, operative reports and follow up consultation notes if available, as well as the time to recurrence are helpful. Current urethral management such as intermittent catheterization should be known. An assessment of the patient's current voiding symptoms and measurement of uroflow and post void residual are essential. As per the American Urological Association (AUA) urethral stricture guidelines a recent assessment of the urethra including either cystoscopy, retrograde urethrogram (RUG) or voiding cystourethrogram (VCUG) should be performed.<sup>11</sup> One should pay particular attention to the length of the stricture, the adjacent diameter of the healthy urethral lumen, and any other notable findings such as sequential strictures.

When selecting a balloon diameter, choose one that is slightly greater than the diameter of the healthy urethra adjacent to the distal edge of the stricture. The most commonly used balloon diameter in the bulbar urethra is 30 French. Additionally, 18, 24 and 36 French balloons are also available, with all diameters available in 3 and 5 centimeter lengths. Importantly, select a balloon length that is a minimum of 1 centimeter longer than the stricture. If the stricture is greater than 2 centimeters a 5-centimeter balloon should be chosen.

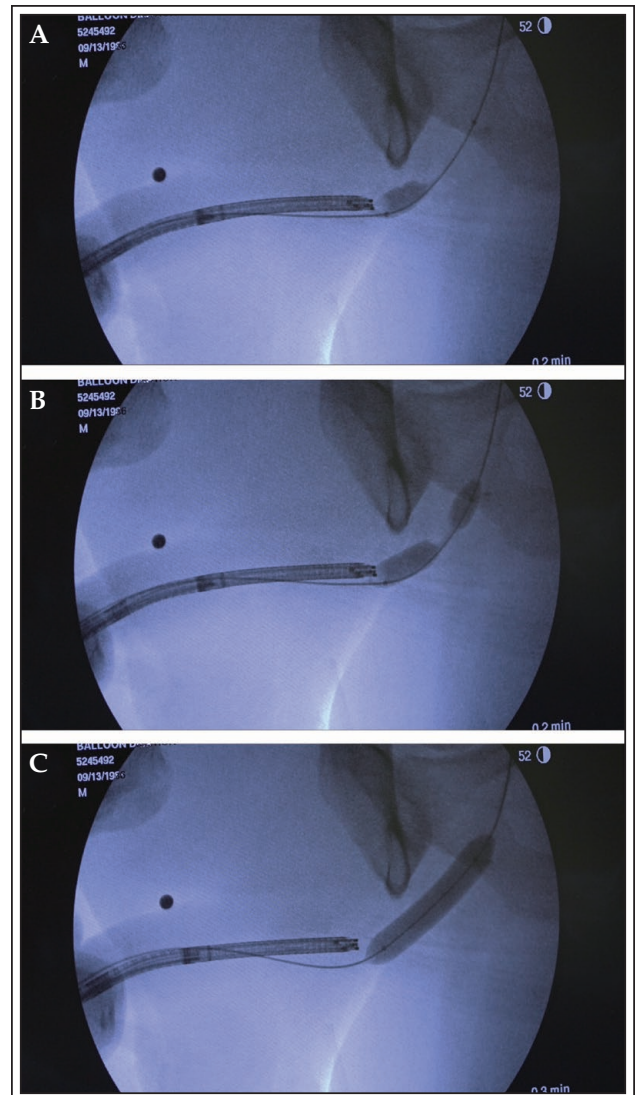
Of note, the Optilume procedure can be performed with rigid cystoscopy in the operating room or with flexible cystoscopy in a clinic setting. Fluoroscopy is not a must at the time of the procedure as long as the stricture length and location has been adequately assessed preoperatively.

To begin the procedure, prep the Optilume catheter for use by purging air from the system. A standard inflation device with pressure gauge rated for at least fifteen atmospheres, is filled with saline or a 50:50 contrast:saline mix, and attached to the Optilume device. Evacuate air by drawing back plunger on inflation device. Once air is removed, turn stopcock to "off" to prevent additional air from entering system.

Insert a cystoscope and place a 0.038" guidewire through the working channel. Position guidewire with the flexible tip coiled in the bladder. If the stricture is too tight to allow the guidewire to pass, filiforms and followers or pollack ureteral catheters may be utilized. In order to facilitate smooth passage over the guidewire, flush the guidewire lumen with water or saline. Remove and discard the balloon protector, Figure 2, from the tip of the Optilume. Minimize handling and do not wipe the balloon with dry, wet or lubricated gauze, or any solvent that could damage the integrity of the drug coating.



**Figure 2.** Balloon protector has been pulled off balloon prior to use.



**Figure 3.** Fluoroscopic images during Optilume procedure. **A)** A wire has been placed through the urethral stricture and into the bladder, the flexible cystoscope has been advanced just distal to stricture, and the Optilume balloon begins to be filled with contrast. Note radio-opaque markers on proximal and distal balloon seen over the guidewire. **B)** The partially-inflated Optilume balloon shows a narrowing, approximately 1.5 cm long, indicating proper placement proximally and distally on the bulbar urethral stricture. **C)** Optilume is fully inflated over guidewire and alongside flexible scope. Inflation is complete to recommended pressure. Inflated balloon spans area of previously seen stricture and no "waisting" can be seen.

The Optilume may be safely passed over a wire through the 6 Fr working channel of a rigid cystoscope, or passed alongside a flexible cystoscope, Figure 3a.

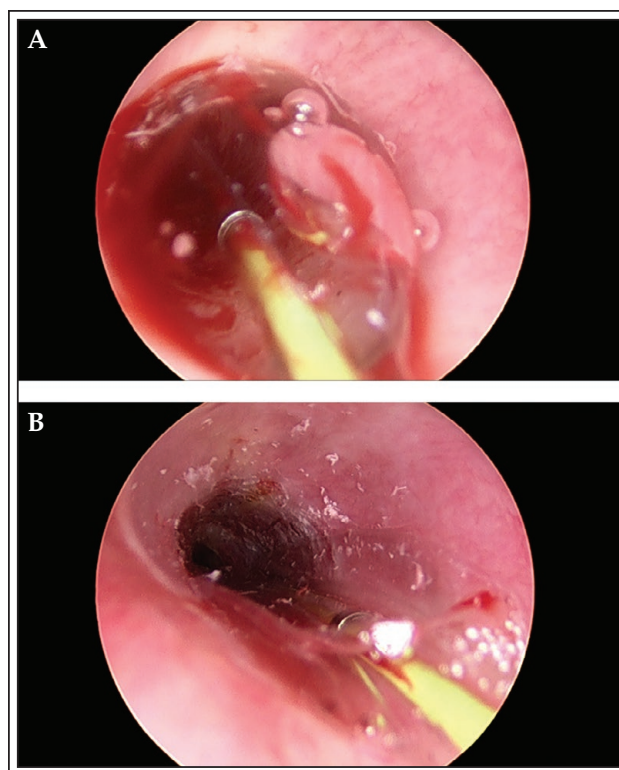
Use the cystoscope to visually guide the placement of the balloon. Position the Optilume device across the stricture with the cystoscope placed distal to the balloon. Ensure that at least one-half centimeter of the balloon extends distally beyond the end of the stricture, with the midpoint of the balloon aligned as close as possible to the midpoint of the stricture, Figure 3. This will enhance the stability of the balloon during inflation and may help ensure uniform optimal dilation. For proper drug delivery to the target stricture, allow the drug-coated balloon to hydrate in the urethra for a minimum of 60 seconds prior to inflation.

If utilizing fluoroscopy, check that the balloon's radiopaque markers are in the correct position, namely distal and proximal to the stricture, Figure 3c. These markers are located at the shoulders of the balloon, indicating where the drug-coated section of the balloon begins and ends. Filling with contrast solution allows for fluoroscopic confirmation of stricture dilation and identification of any significant necking across the stricture segment. Ensure that the stopcock is set to the "open" position. Of note, if the pressure gauge is rising and the balloon is not inflating, the stopcock is in the off position.

Slowly inflate the balloon to the rated burst pressure using the inflation device. If fluoroscopy is used and the balloon filled with contrast, an image can be taken at about 2 ATM of inflation pressure. This will show an outline of the stricture and confirm proper placement. During inflation, the surgeon or surgical assistant should visualize the balloon, Figure 4a, and apply gentle traction on the Optilume catheter to prevent balloon migration. If the balloon begins to migrate, stop inflation immediately and reposition the balloon in order to prevent drug being delivered outside of the desired area.

The rated burst pressure should not be exceeded as inflation beyond the rated burst pressure may cause the balloon to rupture. Refer to product label for rated burst pressures since the pressures vary slightly by balloon size. For the 18 and 24 French balloon diameters the ideal pressure is 12 ATM, for the 30 French balloon the ideal pressure is 10 ATM, and for the 36 French balloon the ideal pressure is 8 ATM.

During inflation, a drop in pressure may be seen at the point where the stricture yields. When this happens, increase pressure until rated burst pressure is achieved. Maintain pressure for a minimum of 5 minutes to transfer the drug and achieve the desired dilation. To optimize stricture dilatation, inflation times of greater than 5 minutes may be performed at the discretion of the surgeon, for particularly dense, fibrous strictures.



**Figure 4.** A) Direct visualization of inflated Optilume. B) Post-treatment deflation of balloon with visible coating adherent to urothelium.

Deflate balloon by withdrawing the inflation device handle and aspirating the balloon. When the balloon is completely deflated, withdraw the balloon slowly. The paclitaxel coating will adhere to the urethral mucosa, Figure 4b. If slight resistance is felt during removal, gently rotate the balloon catheter to help the balloon fold around the catheter shaft to facilitate withdrawal. Leave guidewire in place to potentially assist with Foley catheter placement at the end of the procedure.

Do not perform a retrograde urethrogram and do not pass the cystoscopy through the treated area after the balloon is withdrawn. Doing so could adversely affect the amount of paclitaxel transferred into the urothelium and subsequently lead to sub-optimal results.

Placement of a urethral catheter is recommended. The size of the catheter should not exceed 14Fr to prevent the catheter surface of rubbing against the treatment area and interfering with the paclitaxel transfer to the urothelium. The catheter is then removed around 72 hrs postoperatively. After use, dispose of product in accordance with accepted medical practice and applicable local regulations.

### Algorithm

When the patient is initially evaluated, obtaining a thorough history and physical, assessing the patients lower urinary tract symptoms and evaluating the urine flow and post-void residual are essential. Following this assessment, imaging will be of utmost importance in deciding whether or not the patient is a candidate for the Optilume.

Complete assessment of the urethral stricture with imaging may not be available on an emergent basis and therefore the Optilume procedure is best reserved for elective stricture dilation. The patient is a candidate for the Optilume balloon dilation if the stricture location is in the anterior urethra (penile and bulbar). The drug-coated balloon has not been tested in meatal/fossa strictures and posterior urethral strictures/bladder neck contractures. In the future, use of the Optilume in these locations may become an option.

As per AUA urethral stricture guidelines, endoscopic management with either urethral dilation or DVIU maybe offered for the initial treatment of bulbar urethral strictures < 2 cm.<sup>12</sup> The drug-coated balloon could potentially be used as first line treatment, but at this time current clinical data has been limited to use for recurrent strictures and as a second line therapy. For now, this treatment modality should be considered after initial, failed endoscopic management. The AUA urethral stricture guidelines state that the surgeon should offer a urethroplasty, instead of repeat endoscopic management for recurrent anterior urethral strictures following failed dilation or DVIU.<sup>11</sup> The Optilume, showing promising results and a decrease in stricture recurrence after multiple endoscopic procedures would fall into this category and can be offered to patients who have failed initial endoscopic management. Essentially, the drug-coated balloon can be used as a next step

for patients who do not wish to or are unable to proceed with urethroplasty. A clinician may offer an Optilume balloon dilation rather than multiple standard dilations or DVIUs in patients with recurrent stricture disease. Practitioners who do not perform urethroplasty should consider referral to a center with reconstructive expertise if standard approaches and Optilume dilation do not achieve a desired outcome.<sup>11</sup>

At the time of recurrence, assessment of the stricture length is important since the balloon comes in either a 3 cm or 5 cm length and is recommended to extend beyond the stricture for at least 0.5 cm at each end, Figure 5, therefore a 4 cm stricture is the longest that can be treated with this technique, which is longer than recommended by the guidelines. The recurrence rate of strictures < 3 cm treated with the Optilume is currently being assessed.

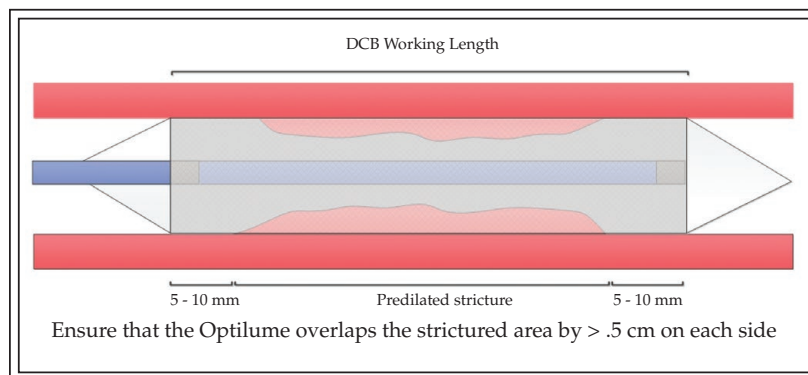
### Discussion

#### *What worked*

For first time Optilume users, performing the procedure in the operating room with the patient asleep might be of benefit, to prevent prolonged discomfort for the patient while getting used to the flow of the dilation technique. Of note, before the operative procedure, it is important to have established that the lumen of the stricture is large enough to accommodate a guidewire. That is best done using cystoscopy in clinic and/or imaging and not letting too much time pass between the assessment and the dilation procedure. This is especially important in a patient with recent placement of a suprapubic tube, since urethral rest can lead to obliteration of the stricture lumen.

In the operating room, using the rigid cystoscope with a 6Fr working channel will make visualization of the balloon placement easiest. Once the practitioner is comfortable using the Optilume, the procedure can be done in clinic, using a flexible cystoscope and passing the guidewire and then treatment balloon along side the flexible cystoscope. For patient comfort an inhaled anesthetic can be useful if available in the clinic setting, such as nitrous oxide or methoxyflurane (Pentrox). In addition, having fluoroscopy available for the first few procedures will be helpful to get a sense of balloon positioning and potential balloon movement during inflation.

A pre-dilation RUG in the OR is helpful as well. Marking the



**Figure 5.** Diagram of recommended overlap of drug-coated balloon working length and stricture.

fluoroscopy screen with a piece of semi-clear tape at the midpoint of the stricture can help with assurance that the balloon is positioned correctly even after pre-dilation when the lumen is as large in the stricture area as it is in the healthy surrounding urethra. If the patient and fluoro unit are unmoved, it will mark the stricture to confirm balloon positioning.

Once the balloon is inflated to the recommended pressure, check the pressure gauge often during the inflation period since the stricture tends to give and the pressure may drop several times and will need to be increased back to the rated burst pressure via the pressure gauge.

It is tempting to move the cystoscope through the treated area once the balloon has been removed since that is usually done during a standard dilation to verify that the lumen is large enough. Resist that temptation and do not pass the treatment area with the scope after the balloon has been removed to prevent the paclitaxel coating from coming off the urothelium.

#### *What did not work*

Waiting too long between urethral stricture assessment and performing the Optilume procedure can be problematic, since the stricture may become impossible to pass with a wire and therefore will no longer be amenable to endoscopic treatment. This can definitely be an issue in patients who had a recent suprapubic tube placed. The urethral rest can lead to complete obliteration of the urethral lumen and therefore assessment of the lumen close in time to performing the dilation is important to ensure that it is still patent.

The use of pre-procedural lidocaine gel in the urethra for analgesia is allowed, especially for in-office treatments to make the procedure more tolerable. Use of post-procedure lidocaine gel is not recommended as it could interfere with drug absorption into the tissue.

Balloon deflation may take some time, usually 1-2 minutes, and a premature attempt to retract the insufficiently deflated balloon into the cystoscope may lead to unnecessary back and forth movement of the device that could interfere with drug adherence to the urothelium. If resistance is experienced on removal of the balloon, fully empty the contents of the inflation device into a basin and reattempt aspiration of the balloon. Once the inflation fluid is no longer flowing back into the inflation device it is safe to remove the balloon.

#### *Management of difficult situations*

The best clinical outcomes come from appropriately sizing the balloon to the healthy urethral lumen

adjacent to the strictured area. Cross sectional measurements from a RUG will aid balloon selection. The goal is to remove the waist in the strictured lumen to achieve a smooth uniform caliber lumen. Fluoroscopy will help with identification of any "waisting".

MacDiarmid et al highlighted the fact that not all strictures will yield under balloon dilation and that DVIU should be used adjunctively in order to achieve a > 20Fr lumen post dilation.<sup>13</sup> For the Optilume procedure, a DVIU as an adjunct post Optilume deployment is not advisable since that may adversely affect the drug adherence to the urothelium. Instead, a standard dilation or DVIU can be used as a neoadjuvant (pre-Optilume deployment) technique to open up the lumen and expose healthy underlying tissue that will facilitate drug absorption. The DVIU is likely to increase drug uptake and may be preferable for dense strictures. Precision must be used in order to prevent "geographic miss" between pre-dilation/DVIU and the Optilume drug-coated balloon application. To prevent the "geographic miss" a pre-dilation RUG is helpful. As mentioned above, marking the fluoroscopy screen with tape to landmark the midpoint of the stricture will help with correct balloon positioning.

#### *Pearl or "trick of the trade"*

- Use pre-dilation or pre-DVIU in the area of the stricture to assure that the urethral lumen reaches the diameter of the surrounding urethra and healthy tissue is exposed for optimal paclitaxel tissue absorption. This is especially important for patients with dense strictures and underlying spongiositis. It is therefore safest to pre-treat a stricture with standard dilation or DVIU to ensure that there is no "waisting" on fluoroscopy before using the drug-coated balloon.
- Once the balloon is inflated to the recommended pressure, check the pressure gauge often during the inflation period since the stricture tends to give and the pressure may drop several times and will need to be increased to the rated burst pressure.
- Do not move through the treated area with the cystoscope and do not turn on your inflow after dilation with the drug-coated balloon is completed in order to prevent rubbing the drug off the urothelium.
- Dilute the contrast mixture filling the inflation device with saline or water by at least 50%. The greater viscosity of "straight" contrast sometimes make deflating the drug-coated or pre-dilation balloon more difficult.

The Optilume procedure is designed to be performed under cystoscopic guidance, to include fluoroscopy if needed. When preparing for an Optilume procedure, the operating room should be set up as if performing a standard balloon dilation. The following specific equipment should also be available.

- Cystoscopic equipment including DVIU and/or dilation instrumentation
- 0.038" Guidewire
- Minimum 20cc balloon inflation device with minimum 15 ATM pressure gauge
- Sterile saline
- Contrast media, if using fluoroscopic guidance
- 10 cc Luer Lock Syringes
- Piston syringe for urethrogram
- 14 French (or smaller) lubricious Foley catheter to be utilized post-procedure

## Conclusions

The Optilume drug-coated balloon represents a step forward in the management of urethral strictures. Previously, repeated urethral dilation or visual internal urethrotomy were offered. After failure of these techniques, men only had the option of urethroplasty. The Optilume drug-coated balloon offers an intermediate step prior to repeated, sometimes lifelong, dilations and urethroplasty. This treatment modality is a promising alternative to current endoscopic management and an option for patients that are poor surgical candidates or decline urethroplasty. The anti-proliferative properties of paclitaxel exerted locally on the scar tissue provide reduced reformation of collagen. □

6. Steenkamp JW, Heyns CF, de Kock ML. Internal urethrotomy versus dilation as treatment for male urethral strictures: a prospective, randomized comparison. *J Urol* 1997;157(1):98-101.
7. Tavakkoli Tabassi K, Yarmohamadi A, Mohammadi S. Triamcinolone injection following internal urethrotomy for treatment of urethral stricture. *Urol J* 2011;8(2):132-136.
8. Kim HM, Kang DI, Shim BS, Min KS. Early experience with hyaluronic Acid instillation to assist with visual internal urethrotomy for urethral stricture. *Korean J Urol* 2010;51(12): 853-857.
9. Chung JH, Kang DH, Choi HY et al. The effects of hyaluronic acid and carboxymethylcellulose in preventing recurrence of urethral stricture after endoscopic internal urethrotomy: a multicenter, randomized controlled, single-blinded study. *J Endourol* 2013;27(6):756-762.
10. Mann RA, Virasoro R, DeLong JM et al. A drug-coated balloon treatment for urethral stricture disease: two-year results from the ROBUST I study. *Can Urol Assoc J* 2020 July. Online ahead of print.
11. Wessells H, Angermeier KW, Elliott S et al. Male urethral stricture: American Urological Association Guideline. *J Urol* 2017;197(1):182-190.
12. Black PC, Friedrich JB, Engrav LH, Wessells H. Meshed unexpanded split-thickness skin grafting for reconstruction of penile skin loss. *J Urol* 2004;172(3):976-979.
13. MacDiarmid SA, Harrigan CT, Cottone JL, McIntyre WJ, Johnson DE. Assessment of a new transurethral balloon dilation catheter in the treatment of urethral stricture disease. *Urology* 2000;55(3):408-413.

---

## References

1. Greenwell TJ, Castle C, Andrich DE, MacDonald JT, Nicol DL, Mundy AR. Repeat urethrotomy and dilation for the treatment of urethral stricture are neither clinically effective nor cost-effective. *J Urol* 2004;172(1):275-277.
2. Veeratterapillay R, Pickard RS. Long-term effect of urethral dilatation and internal urethrotomy for urethral strictures. *Curr Opin Urol* 2012;22(6):467-473.
3. Tonkin JB, Jordan GH. Management of distal anterior urethral strictures. *Nat Rev Urol* 2009;6(10):533-538.
4. Santucci R, Eisenberg L. Urethrotomy has a much lower success rate than previously reported. *J Urol* 2010;183(5):1859-1862.
5. Virasoro R, DeLong JM, Mann RA et al. A drug-coated balloon treatment for urethral stricture disease: Interim results from the ROBUST I study. *Can Urol Assoc J* 2020;14(6):187-191.