

How I Do It: Modification of technique to safely position patients with super obesity in dorsal lithotomy for ureteroscopic management of kidney stones

Jordan Allen, MD, Necole M. Streeper, MD

Division of Urology, Penn State Milton S. Hershey Medical Center, Hershey, Pennsylvania, USA

ALLENJ, STREEPERNM. How I Do It: Modification of technique to safely position patients with super obesity in dorsal lithotomy for ureteroscopic management of kidney stones. *Can J Urol* 2020;27(6):10488-10491.

Obesity is a known risk factor for recurrent nephrolithiasis and it can be challenging to provide safe surgical intervention in the super obese population. Despite high weight limits on surgical beds, these often do not take into account positioning the patient on the end of the bed for dorsal lithotomy, which can risk an unsteady bed. In addition, depending on patient habitus the leg stirrups may not accommodate. There is limited literature that discusses the technical approach for positioning super

obese patients in dorsal lithotomy when the weight limit approaches or exceeds the capacity of equipment available. In this article, we present a modified positioning technique to improve bed stability, which also provides an alternative if the patient's legs are not supported by available leg stirrups. From our experience, this modified dorsal lithotomy positioning for ureteroscopy is feasible and safe in patients with super obesity. Surgical intervention on this population requires appropriate planning and teamwork to ensure safe positioning.

Key Words: kidney stones, obesity, super obesity, ureteroscopy, safe positioning, dorsal lithotomy

Introduction

The prevalence of obesity continues to rise worldwide, with the latest estimate that 42.4% of American adults are classified as obese.¹ Obesity is measured most

commonly by body mass index (BMI, kg body weight/height in m²) and is defined as BMI > 30 kg/m². With an increased incidence of even higher BMI, some clinicians use the terms morbidly obese if BMI is ≥ 40 kg/m² and super obese if BMI ≥ 50 kg/m². Studies suggest that obesity is independently associated with a greater risk of kidney stone disease and increased surgical morbidity.²⁻⁴ Nephrolithiasis is common and affects an estimated 8.8% of American adults annually with prevalence higher among the obese.⁵ Urologists are increasingly challenged with providing safe and effective surgical treatment for this population.

Accepted for publication September 2020

Address correspondence to Dr. Necole M. Streeper, Division of Urology, Penn State Milton S. Hershey Medical Center, Mail Code H055, 500 University Drive, PO Box 850, Hershey, PA 17033-0850 USA

How I Do It: Modification of technique to safely position patients with super obesity in dorsal lithotomy for ureteroscopic management of kidney stones

Ureteroscopy (URS) has been found to be a safe and effective treatment option in obese patients.⁶⁻⁹ However, few studies included patients with super obesity and extreme BMI > 70-80 which can present additional technical challenges that must be considered during preoperative planning. Patients undergoing URS with laser lithotripsy for treatment of kidney stones are placed in dorsal lithotomy positioning. This requires the patient to be moved to the very end of the bed to accommodate the C-arm fluoroscopy underneath. Despite bed weight limits of 1,000-1,200 lbs (454-544 kg) there are instances where the bed can tip or be visibly unsteady. In addition, dorsal lithotomy requires placing the legs into stirrups, which come in different models (Yellofins (350 lbs, 159 kg), Yellofins Elite (500 lbs, 227 kg), and Ultrafins (800 lbs, 363 kg)). However, some patients will exceed the capacity, especially in cases of severe lower extremity lymphedema.

There is limited literature that discusses the technical approach for positioning super obese patients in dorsal lithotomy when the weight limit or body habitus approaches or exceeds the capacity of equipment available. We describe technical modifications using existing equipment that can be made to perform safe dorsal lithotomy positioning for URS in patients with super obesity.

Method and technique

In our practice, we cared for a super obese patient (BMI of 85 kg/m² (weight = 234 kg or 516 lbs)) with severe bilateral lower extremity lymphedema and symptomatic right staghorn calculus, see Figure 1. Unfortunately, her skin-to-stone distance was too great to safely perform percutaneous nephrolithotomy

with our available instrumentation. Thus, she was counseled and she elected for staged URS. Her severe bilateral lower extremity lymphedema was incompatible with even the largest Ultrafin stirrups available, making dorsal lithotomy positioning challenging. Furthermore, her weight of > 500 lbs exceeded the limits of our typical cysto table and required use of a bariatric surgical bed with a weight limit of 1,200 lbs. However, with prior experience, there was a concern that the table would be at risk of tipping with the weight centered at the end of the table for dorsal lithotomy.

We designed a modified dorsal lithotomy positioning technique to improve bed stability and safely position the patient's legs without the use of stirrups. The surgical bed was first lined with gel padding to reduce the risk of pressure injury. Bed extenders x 4 were placed on both sides of the bed, see Figure 2. An inflatable bariatric hover mattress (Stryker Glide) was used to transfer the patient from the transport bed to the operating table. It was essential to have the patient placed on the inflatable bariatric hover mat prior to coming to the operating room. This made it easier to move the patient to the surgical bed and was left in place deflated under the patient for the duration of surgery. Ergo-step stools were assembled to support the patient's legs in a modified dorsal lithotomy position, see Figures 2 and 3 for configuration. The step stools were used to provide additional stability to the end of the bed, with the end of the table resting on the step stools on each side.

It was necessary to have additional personnel for positioning the patient, typically 12 including four on each side, one for each leg and two anesthesia providers at the head. When transferring the patient to the surgical bed it is important to have one person

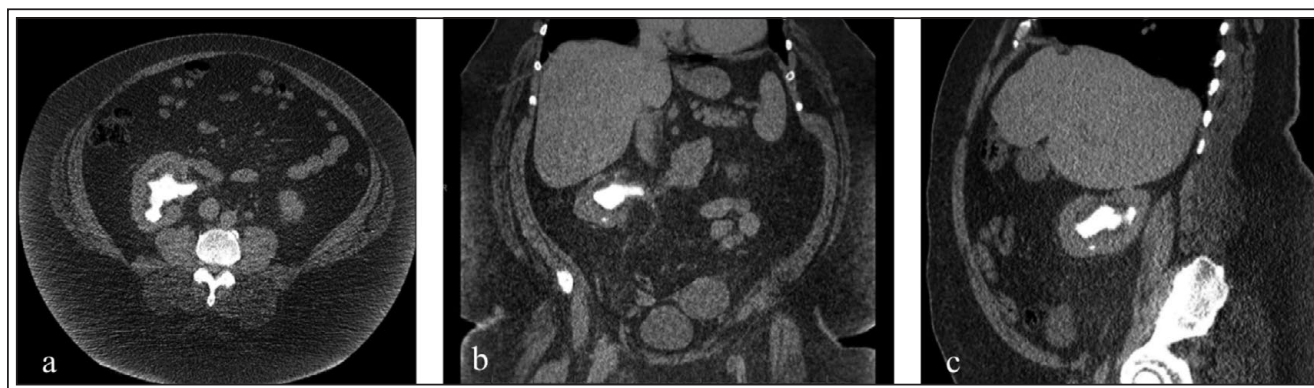

Figure 1. Super obese patient (BMI 85) with large volume right-sided stone a) axial b) coronal and c) sagittal images from CT abdomen and pelvis demonstrating right staghorn calculus.




Figure 2. Bed preparation prior to patient positioning. **a)** Bed was padded with gel pads. Extenders were added to both sides to accommodate patient. **b)** Ergo-step stools were configured at the base of the bed to prevent bed from tipping with patient in position. A bariatric hover mattress was left on the operating table to aid in transfer of patient back to the transport bed following the procedure.

designated to give direction to the team. It is helpful to first go over a game plan prior to execution in this situation. Taking time to do it in a stepwise manner will ensure it is done safely. Patient was positioned

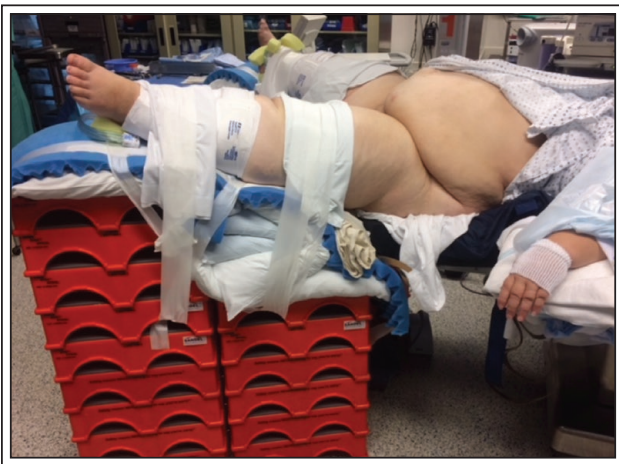

Figure 3. Side profile of modified dorsal lithotomy positioning. Ergo-step stools stacked in graduated fashion for ergonomic leg positioning in modified dorsal lithotomy positioning. For desired slope, 9 stools were stacked under each foot and 6 under each thigh. Pillows and foam rolls were used for pressure point padding and fine tunings. Legs were secured to leg supports with 2 inch silk tape.

optimally for induction and intubation by the anesthesia team and then re-positioned with the assistance of the hover mattress so that the patient's perineum was flush with the end of the bed. The patient was secured to the table and appropriate padding of all pressure points was ensured. The entire set up prior to start of the case took an additional hour, so would advise to plan accordingly. It was important to limit the amount of time the patient was in this position so we were prepared to move quickly with securing to the table, prepping and draping. Standard cysto drapes were used with additional drape sheets for each leg. Radiology personnel were immediately available to position the C-arm. See Figure 4, shows the placement of the steps to ensure the C-arm is able to maneuver into position.

The patient had a full staghorn calculus so URS was done in a staged approach and it took a total of six surgeries. In one of the initial surgeries she developed minor rhabdomyolysis secondary to attempting a more prolonged surgery (3 hours) that was treated with sodium bicarbonate in IV fluids and did not result in kidney injury. Immediately postoperatively she complained of severe lower back and buttocks pain. Her urine was dark brown and urine myoglobin was elevated. In addition, her CPK was elevated to 15,000 and down trended on post-op day (POD) 2 to normal levels by POD 10. Her pain improved by POD 1 and completely resolved by POD 10. From this experience, to reduce risk of future episodes of rhabdomyolysis, we placed even more gel padding on the table and limited the time for surgery to 2 hours from the time she was moved onto the surgical bed. We also placed

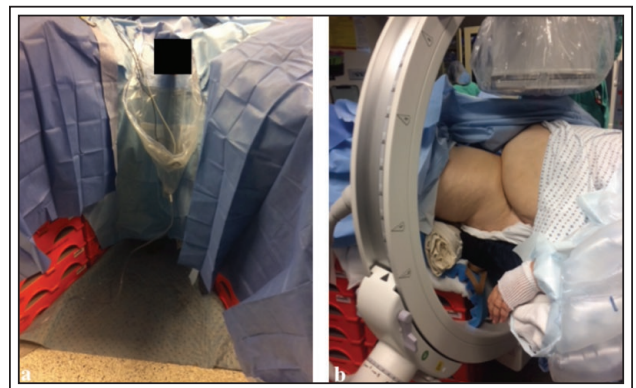


Figure 4. Final set up with sterile drapes and C-arm in place. **a)** With drapes in place, modified set up resembles traditional dorsal lithotomy positioning. **b)** Set up permits C-arm access to patient. C-arm is draped to prevent contamination of sterile field.

How I Do It: Modification of technique to safely position patients with super obesity in dorsal lithotomy for ureteroscopic management of kidney stones

her into position on the surgical bed prior to general anesthesia induction to ensure she was comfortable before proceeding. She had no additional issues or complications. Prior to stent removal she had CT scan imaging that showed non-obstructing small residual fragments that appeared to be layering within three calyces, with cumulative size of 1.1 cm, 6 mm, and 5 mm in each calyx. At follow up her pain that she had preoperatively had resolved and she was able to perform activities of daily living that she was unable to do prior to treatment. She has not required additional surgical intervention.

Discussion

With increasing prevalence of obesity, and as an independent risk factor for kidney stone disease, it is important for urologists to be familiar with properly positioning super obese patients for surgical intervention. We describe a novel modification of technique to position into dorsal lithotomy that provides a safe, effective strategy for URS in the super obese population.

The patient in this case did well with staged URS treatment of her staghorn calculus. It required multiple procedures, however postoperatively she had satisfactory stone clearance and her quality of life improved significantly. There was no significant patient or healthcare personnel injury secondary to patient positioning. Furthermore there were no concerns with bed instability. She had mild rhabdomyolysis after a prolonged surgery, however did not have permanent kidney damage. Adjustments were made to ensure additional padding and surgical time was limited for the remaining surgeries. She had no additional surgical morbidity.

Surgical intervention on the super obese population presents technical challenges that must be considered. However, with appropriate preoperative planning these obstacles may be overcome. The key points are additional padding to the surgical bed, use of step stools to provide bed stability, having adequate personnel, use of an inflatable bariatric hover mattress and limiting the surgical time once patient is on the surgical bed. Overall we found this technique to be a safe, effective strategy for dorsal lithotomy in the super obese patient.

Conclusions

In this article, we present a modification of technique to safely position super obese patients in dorsal lithotomy for URS with laser lithotripsy to treat

kidney stones. This novel technique improves bed stability and provides an alternative if the patient's legs are not supported by available leg stirrups. From our experience this reduces the risk of patient and healthcare worker injury from an unsteady bed, and reduces the fear of the bed tipping. Suggesting that this modified technique is feasible and safe in patients with super obesity when patient habitus prohibits use of standard equipment. Surgical intervention on this population requires appropriate planning and teamwork to ensure safe positioning. □

References

1. Hales CM, Carroll MD, Fryar CD, Ogden CL. Prevalence of obesity and severe obesity among adults: United States, 2017-2018. *NCHS Data Brief* 2020;360:1-7.
2. Taylor EN, Stampfer MJ, Curhan GC. Obesity, weight gain, and the risk of kidney stones. *JAMA* 2005;293(4):455-462.
3. Flegal KM, Kit BK, Orpana H et al. Association of all-cause mortality with overweight and obesity using standard body mass index categories: a systematic review and meta-analysis. *JAMA* 2013;309(1):71-82.
4. Krambeck A, Wijnstok N, Olbert P et al. The influence of body mass index on outcomes in ureteroscopy: results from the Clinical Research Office of Endourological Society URS Global Study. *J Endourol* 2017;31(1):20-26.
5. Scales CD, Smith AC, Hanley JM et al. Urologic diseases in America Project. Prevalence of kidney stones in the United States. *Eur Urol* 2012;62(1):160-165.
6. Chew BH, Zavaglia B, Paterson RF et al. A multicenter comparison of the safety and effectiveness of ureteroscopic laser lithotripsy in obese and normal weight patients. *J Endourol* 2013;27(6):710-714.
7. Best SL, Nakada SY. Flexible ureteroscopy is effective for proximal ureteral stones in both obese and nonobese patients: a two-year, single-surgeon experience. *Urology* 2011;77(1):36-39.
8. Dash A, Schuster TG, Hollenbeck BK et al. Ureteroscopic treatment of renal calculi in morbidly obese patients: a stone-matched comparison. *Urology* 2002;60(3):393-397.